

Distal Radioulnar Joint Arthroscopy and the Volar Ulnar Portal

David J. Slutsky, MD, FRCS(C)

Department of Orthopedics
Harbor-UCLA Medical Center
Torrance, CA

ABSTRACT

Pain on the ulnar side of the wrist remains poorly understood. As attention has shifted toward the myriad causes of ulnar-sided wrist pain, the utility of viewing the wrist from a volar ulnar (VU) perspective has emerged. Lunotriquetral ligament tears have been implicated in the pathogenesis of volar intercalated segmental instabilities. They often originate in the palmar subregion, which is most important for maintaining stability. These tears are difficult to visualize through the 4, 5, or 6R portals. They are well seen through a VU portal, and the direct line of sight facilitates debridement. The VU portal has potential use in the arthroscopic diagnosis and treatment of patients with injuries to the ulnar sling mechanism. It aids in triangular fibrocartilage repairs especially those involving the dorsal aspect between the ulnar styloid and the radial insertion, because the proximity of the 4, 5, and 6R portals makes triangulation of the instruments difficult.

Although arthroscopy of the dorsal aspect of the distal radioulnar joint has been well described, it has largely remained a curiosity, with few clinical indications. Recent biomechanical studies have highlighted the importance of the deep attachment of the triangular fibrocartilage complex in maintaining distal radioulnar joint stability. The volar distal radioulnar portal is useful for assessing the foveal attachment. It may be used where there is the suspicion of a peripheral triangular fibrocartilage detachment due to a loss of its normal tension despite the lack of a visible tear during radio-carpal arthroscopy. The judicious use of these portals deserves consideration for inclusion as part of a thorough arthroscopic examination of selected patients with ulnar-sided wrist pain.

Keywords: arthroscopy, DRUJ, volar, portal

Address correspondence and reprint requests to David J. Slutsky, MD, FRCS(C), Department of Orthopedics, David Geffen School of Medicine, University of California Los Angeles, South Bay Hand Surgery Center, Suite F, 3475 Torrance Blvd, Torrance, CA 90503.
E-mail: d-slutsky@msn.com.

HISTORICAL PERSPECTIVE

The indications for wrist arthroscopy have steadily grown from a mostly diagnostic tool to a valuable adjunctive procedure in the treatment of myriad wrist disorders. The ulnocarpal joint has been the proverbial “black box” of the wrist pain. Instability of the distal radioulnar joint (DRUJ) is a hotbed for research, with new and innovative techniques appearing monthly. Although the new generation of 3-T magnetic resonance imaging scanners holds promise for the future, many of the causes of ulnar-sided wrist pain are revealed only at the time of arthroscopy. Establishing the diagnosis of a peripheral detachment of the triangular fibrocartilage complex (TFCC) or a tear of the ulnar sling mechanism remains an exacting challenge even for the experienced arthroscopist.

The clinical utility of volar portals has been recently elucidated.¹ As kinematic and biomechanical studies have shed light on the role of the dorsal capsular structures and palmar subregions of the interosseous ligaments in maintaining carpal stability, it has become prudent to view the wrist from a palmar perspective. Volar portals for wrist arthroscopy have certain advantages over the standard dorsal portals for visualizing dorsal capsular structures as well as the palmar aspects of the carpal ligaments.

Tears of the lunotriquetral (LT) ligament have been implicated in the pathogenesis of volar intercalated segmental instabilities.² The LT ligament consists of dorsal, proximal, and palmar subregions. The palmar subregion is the most important for maintaining stability. Sectioning the proximal and dorsal components of the LT ligament has little effect on carpal kinematics. Sectioning the proximal and palmar components of the ligament, however, results in a volar intercalated segmental instability that is increased if there is a coexisting rupture of the dorsal radiocarpal ligament.³ Ligament tears often originate in the palmar subregion. In the study of 20 patients who underwent arthroscopy for LT ligament tears by Osterman et al,⁴ the most common site of the tear was palmar and central, with intact dorsal fibers.

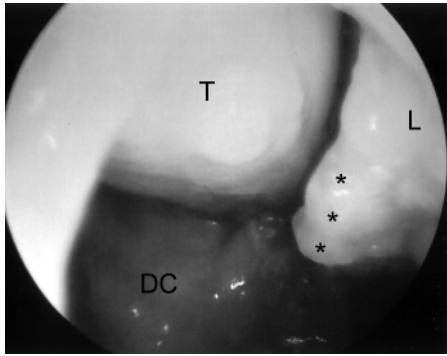


FIGURE 1. Palmar LT ligament tear. View of a palmar lunotriquetral interosseous ligament tear using a dry technique. Note the avulsed ligament* with the exposed cleft between the lunate (L) and triquetrum (T). DC indicates dorsal capsule.

When viewed from the 4, 5, or 6R portals, it is often necessary to debride the proximal portion of the LT ligament to assess the palmar component. Direct visualization of the LT ligament through a volar portal obviates the need for this.⁵

Pain on the ulnar side of the wrist remains poorly understood, especially when stemming from instability of the distal radioulnar joint. The dorsal radioulnar ligament (DRUL) has been shown to be important for both palmar and dorsal stability of the distal radioulnar joint.^{6,7} The extensor carpi ulnaris subsheath (ECUS) is an integral part of the dorsoulnar capsule, and it is an important stabilizer of the wrist,⁸ but it is poorly seen through a dorsal portal.

Although arthroscopy of the dorsal aspect of the distal radioulnar joint has been well described,⁹ it has largely remained a curiosity, with few clinical indications. Of late, biomechanical studies have highlighted the importance of the deep attachment of the TFCC for maintaining stability of the distal radioulnar joint.¹⁰ Moritomo recently described a palmar repair method of the foveal insertion of the TFCC through an open volar ulnar (VU) approach using a suture anchor (International Wrist Investigator's Workshop; September 2006; Washington, DC). As attention has shifted toward the multitudinous causes of ulnar-sided wrist pain, the indication for the judicious use of a volar ulnocarpal portal and volar DRUJ portal have emerged.

INDICATIONS

Volar Ulnar Portal

The VU portal is useful for visualizing and debriding palmar tears of the LT ligament (Fig. 1). It also aids in the repair or debridement of dorsally located TFCC tears, because the proximity of the 4j, 5, and 6R portals makes triangulation of the instruments difficult.⁵

The VU portal provides unparalleled views of the DRUL and the dorsal ulnar wrist capsule (Fig. 2). Watson and Weinzweig²⁰ has described a detachment of the ulnar sling that encompasses the entire ulnar cuff of ligamentous collagen ulnar to the radius. It contains the ulnar collateral ligament and the ECUS (Fig. 3). Chronic impingement of a detached ulnar sling on the triquetrum has been implicated as a cause of wrist pain. He has recommended an open excision of the ulnar most segment of the displaced fibrous cuff. The VU portal has potential use in this condition.

When examined from a coronal perspective, the ulnar styloid lies relatively dorsal on the end of the ulnar head. The DRUL drapes over the dorsal aspect of the ulnar head as it converges toward the fovea. These factors limit the field of view and make it difficult to insert anything larger than a 1.9-mm scope through a dorsal DRUJ portal. There is more room on the VU aspect of the DRUJ for insertion of an arthroscope, with relatively unimpeded views of the proximal articular disk and foveal attachments. The dorsal DRUJ portals remain useful, however, for outflow and instrumentation (Figs. 2A, B).

Volar Distal Radioulnar Portal

The volar distal radioulnar (VDRU) portal is useful for assessing the deep foveal attachment of the TFCC. It

may be used in cases where the suspicion of a peripheral TFCC detachment remains despite the absence of any visible tears.^{21,22} Fibrillation and/or partial-thickness tears of the deep surface of the articular disk may occur before perforation, which are readily identified.²³

Tomaino and²⁴ has recently described a wafer resection through an intact TFCC for the treatment of ulnar impaction syndrome. Use of the VDRU portal may negate the need for establishing a working portal through the intact articular disk. This portal is also useful for

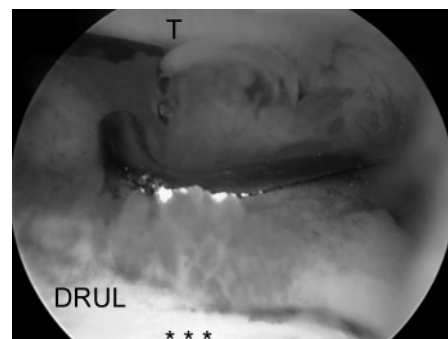


FIGURE 2. Dorsal radioulnar ligament. When viewed from the VU portal, the DRUL is seen as a thickening of the dorsal aspect of the TFC* as it blends into the dorsal capsule. Note the inflamed and hypertrophic synovium. The probe has been placed in the 4j/5 portal. T indicates triquetrum.

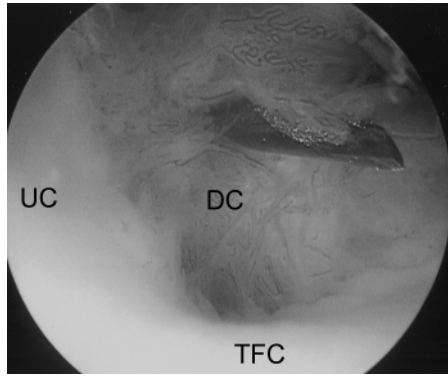


FIGURE 3. View of the dorsal ulnar capsule with synovitis. A needle has been placed through the ECUS to locate its position arthroscopically. UC indicates ulnar collateral ligament; DC=dorsal capsule. Note the florid synovitis.

assessing the completeness of a wafer resection, because it is often difficult to resect the ulnar dome completely through the TFC perforation without extreme pronation and supination of the wrist and artful maneuvering of the arthroscope.

Dorsal DRUJ portals

F4 Two dorsal DRUJ portals have been described (Figs. 4A, B).⁵ In concert with the VDRU portal, the dorsal DRUJ portals may be used to more completely assess the status of the articular cartilage of the ulnar head and sigmoid notch. This information may be useful in cases of DRUJ instability or when there is the suspicion of early osteoarthritis, in which case, arthroscopy may differentiate between the need for DRUJ stabilization and ulnar head excision/arthroplasty.

| CONTRAINDICATIONS

Contraindications to the use of the VU portal and DRUJ portals would include any cause of marked swelling, which distorts the topographic anatomy, fractures involving the sigmoid notch or ulnar head, large capsular tears that might lead to extravasation of irrigation fluid, neurovascular compromise, bleeding disorders, or infection. Unfamiliarity with the regional anatomy is a relative contraindication.

| RELEVANT ANATOMY

The triangular fibrocartilaginous complex has been well described. It consists of the articular disk, meniscus homologue, palmar radioulnar ligament (PRUL), DRUL, ECUS, ulnar capsule, and the ulnolunate and ulnotriquetral ligaments.^{11,12} The PRUL and DRUL contain a superficial and a deep portion that are conjoined at the radius attachment. The superficial portion surrounds the articular disk but has no clear

definable insertion into the ulnar styloid. The fibers of the deep portion of the DRUL and the PRUL interdigitate to form a conjoined tendon as they converge toward their insertion into the fovea at the base of the ulnar styloid (

Figs. 5A, B). The foveal insertion has a **F5** greater effect on stability than the styloid insertion. Recent work suggests that DRUJ instability may be caused by ulnar detachment.¹³ With an intact foveal ligament attachment, patients still may experience peripheral TFCC tear, but they may not experience the same instability as those with a total avulsion of the ulnar ligament attachments, which can be seen with an

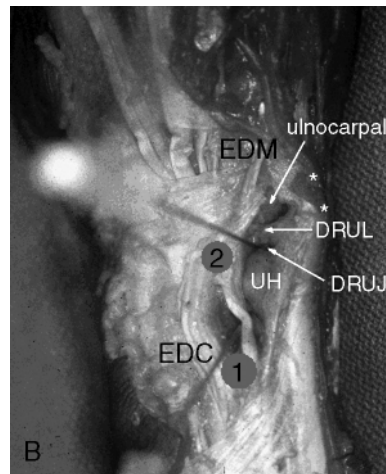
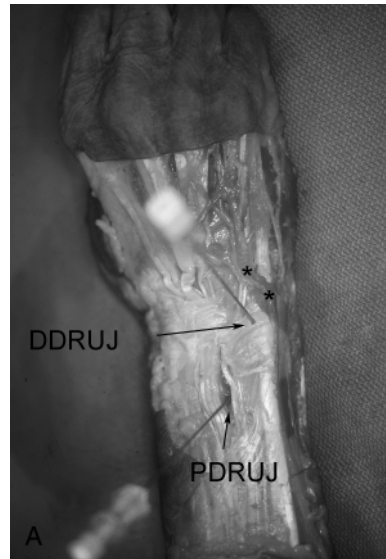
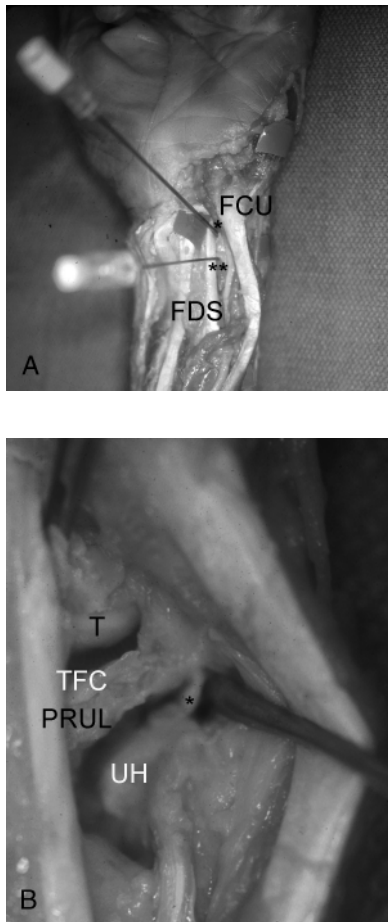


FIGURE 4. Dorsal DRUJ portals. A, Relative positions of the proximal (PDRUJ, circle 1) and distal (DDRUJ, circle 2) portals in relation to the dorsal cutaneous branch of the ulnar nerve. *B, Close-up view of the portals with a needle in the ulnocarpal joint and dorsal DRUJ. ECU indicates extensor carpi ulnaris; EDM, extensor digiti minimi; UH, ulnar head.



FIGURES. Volardistalradioulnarportal. A, Relative positions of the VU and VDRU portals. B, Close-up view of the VDRU portal. Note the foveal attachment of the deep fibers* of the PRUL. FCU indicates flexor carpi ulnaris; FDS, flexor digitorum sublimis; T, triquetrum; UH, ulnar head.

avulsion fracture of the entire ulnar styloid.¹⁰ The ligamentum subcrucium is an inconstant region of vascularized connective tissue that lies between the foveal attachment and the ulnar styloid but by itself provides little mechanical support.

Portal Anatomy

Dorsal Radioulnar Portals. Both a proximal and distal dorsal radioulnar joint portal have been described. They lie between the tendons of the extensor carpi ulnaris and the extensor digiti minimi. Transverse branches of the DCBUN were the only sensory nerves near these portals, at a mean of 17.5 mm distally (range, 10Y20 mm).

Volcar Ulnar Portal. In a cadaver study performed by the author, a VU portal was established via a 2-cm longitudinal incision made along the ulnar edge of the finger flexor tendons at the proximal wrist crease.⁵ The VU portal exploits the same surgical interval as the palmar

ulnar approach to the distal radius, which is used in the treatment of displaced articular fractures. The flexor tendons were retracted radially and a trocar was introduced into the radiocarpal joint. The ulnar styloid marked the proximal point of the VU portal, approximately 2 cm distal to the pronator quadratus. The portal was in the same sagittal plane as the ECUS and penetrated the ulnolunate ligament adjacent to the radial insertion of the TFC. The ulnar nerve and artery were generally more than 5 mm from the trocar, provided the capsular entry point was deep to the ulnar edge of the profundus tendons. The palmar cutaneous branch of the ulnar nerve (nerve of Henle¹⁶) was highly variable and not present in every specimen. This inconstant branch provides sensory fibers to the skin in the distal ulnar and volar part of the forearm to a level 3 cm distal to the wrist crease. Its territory may extend radially beyond the palmaris longus tendon.

¹⁶ This branch tends to lie just to the ulnar side of the axis of the fourth ray, but it was absent in 43% of specimens in one study.¹⁷ Martin et al¹⁸ demonstrated that there was no true internervous plane because of the presence of multiple ulnar-based cutaneous nerves to the palm, which puts them at risk with any ulnar incision. Because there is no true safe zone, careful dissection and wound-spread technique should be observed.

Volcar Distal Radioulnar Portal. The topographical landmarks and establishment of the VDRU portal are identical to those of the VU portal. The capsular entry point lies 5 to 10 mm proximally.¹⁹

TECHNIQUE

It is useful to have a systematic approach to viewing the wrist. The structures that should be visualized as a part of a standard exam include the radius articular surface, the proximal scaphoid and lunate, the scapholunate and lunotriquetral (LTIL) interosseous ligaments, both palmar and dorsal, and the radial and peripheral TFCC

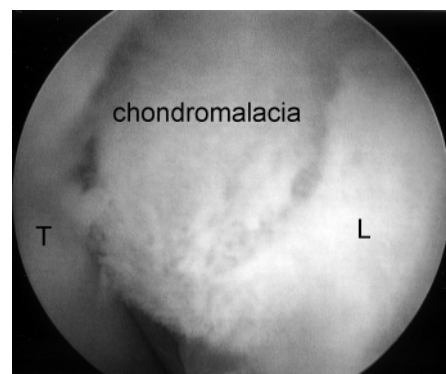


FIGURE 6. Chondromalacia of the palmar aspect of the lunate (L). T indicates triquetrum.

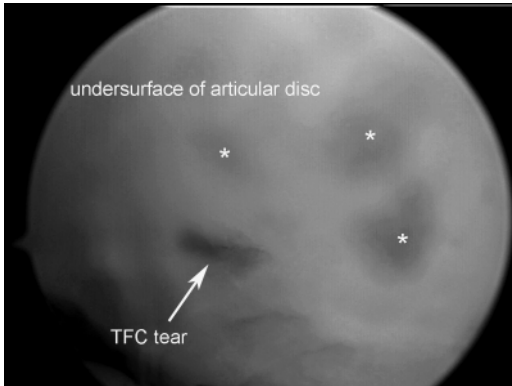


FIGURE 7. Proximal TFC tear. The undersurface of the articular disc demonstrates synovitis* along with a central tear.

attachments. It is my practice is to establish the dorsal portals first, and then start the arthroscopic examination with a volar radial portal to visualize the palmar scapholunate interosseous ligament and the dorsal radiocarpal ligament first to minimize any error from iatrogenic trauma to the dorsal capsular structures.²⁶ This is followed by the VU portal to assess the palmar LTIL and DRUL, the ECUS, and the TFCC. The scope is next inserted in the 3j/4 portal, followed by various combinations of the 4j/5 portal and 6R portal. The 6U portal is mostly used for outflow but may be used for instrumentation when debriding palmar LTIL tears. Midcarpal arthroscopy is then performed to assess the integrity of the intercarpal ligaments and inspect for chondral lesions.

Volar Ulnar Portal

The VU portal is established via a 2-cm longitudinal incision centered over the proximal wrist crease along the ulnar edge of the finger flexor. The tendons are retracted to the radial side, and the radiocarpal joint space is identified with a 22-gauge needle. Blunt tenotomy scissors or forceps are used to pierce the volar capsule, followed by insertion of a cannula and blunt trocar then the arthroscope. Care is taken to situate the cannula beneath the ulnar edge of the flexor tendons and to apply retraction in a radial direction alone to avoid injury to the ulnar nerve and artery. The median nerve is protected by the interposed flexor tendons. The palmar region of the LTIL can usually be seen slightly distal and radial to the portal. A hook probe is inserted through the 6R or 6U portal.

Volar Distal Radioulnar Portal

The VDRU portal is accessed through the VU skin incision. A 1.9-mm small joint arthroscope can be used because gaining access to the DRUJ can be difficult, especially in a small wrist but I have found that a

standard 2.7-mm scope provides a better field of view. The ulnocarpal joint is first identified as described above. It is useful to leave a needle or cannula in the ulnocarpal joint for reference during this step. The DRUJ is then located by angling a 22-gauge needle 45 degrees proximally and then injecting the DRUJ with saline. Alternatively, the skin incision can be extended proximally for 1 cm so that it lies at the same level as the VDRU capsular entry point. Once the correct plane is identified, the volar DRUJ capsule is pierced with tenotomy scissors, followed by a cannula with a blunt trocar and then the arthroscope. Alternatively, a probe can be placed in the distal dorsal radioulnar joint portal and advanced through the palmar incision to help locate the joint space. It can then be used as a switching stick, over which the cannula is introduced. Initially, the DRUJ space appears quite confined, but over the course of 3 to 5 minutes, the fluid irrigation expands the joint space,

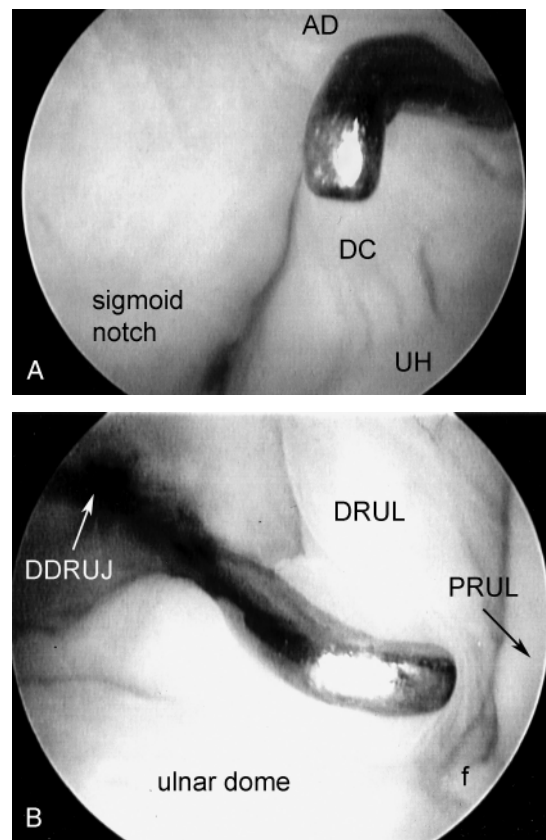


FIGURE 8. View from the VDRU portal. A, The proximal sigmoid notch is well visualized. The dorsal DRUJ capsule can be seen arising from the ulnar head. The probe is in the dorsal DRUJ portal. B, Moving the scope distally and ulnarly, the DRUL and the PRUL can be seen inserting on the fovea. AD indicates articular disk; DC, dorsal DRUJ capsule; DDRUI, dorsal DRUJ portal; f, fovea; UH, ulnar head.

which improves visibility. A burr or thermal probe can be substituted for the 3-mm hook probe through the dorsal DRUJ portal as necessary. The accompanying video illustrates the VU and VDRU portal placement and technique.

Dorsal DRUJ portals

The dorsal radioulnar joint can be accessed through a proximal and distal portal.⁹ The proximal DRUJ portal is located in the axilla of the joint, just proximal to the sigmoid notch and the flare of the ulnar metaphysis. This portal is easier to penetrate and should be used initially to prevent chondral injury from insertion of the trocar. The forearm is held in supination to relax the dorsal capsule and to move the ulnar head volarly. This also lifts the central disk distally from the head of the ulna. Reducing the traction to 1 to 2 lb permits better views between the ulna and the sigmoid notch by reducing the compressive force caused by axial traction. The joint space is identified by first inserting a 22-gauge needle horizontally at the neck of the distal ulna. Fluoroscopy facilitates the needle placement. The joint is infiltrated with saline, and the capsule is spread with tenotomy scissors through a small incision. A small cannula and trocar for the 1.9-mm scope are introduced, followed by insertion of a 1.9-mm 30-degree-angle scope. Entry into this portal provides views of the proximal sigmoid notch cartilage and the articular surface of the neck of the ulna. One should systematically look for loose bodies or synovial hypertrophy.

The distal DRUJ portal is identified 6 to 8 mm distally with the 22-gauge needle and just proximal to the 6R portal. This portal can be used for outflow drainage or instrumentation. It lies on top of the ulnar head but underneath the TFC; hence, it cannot be used in the presence of a positive ulnar variance. The TFC has the least tension in neutral rotation of the forearm, which is the optimal position for visualizing the articular dome of the ulnar head, the undersurface of the TFC, and the foveal insertion of the PRUL. Because of the dorsal entry of the arthroscope, the course of the DRUJ is not visible until its attachment into the fovea is encountered.

27

Author's Own Experience

The VU portal has been used in 47 patients since 1998. The ulnar-sided pathology included 17 tears of the LTIL ligament, 14 TFC tears, and 2 ulnolunate ligament tears. The views through the VU portal facilitated debridement of the palmar region of the LTIL ligament using a resector in the 6R or 6U portals. In 3 of these patients, unrecognized chondromalacia of the palmar aspect of the ulna was identified (

Fig. 6), and 1 patient had chondromalacia of the palmar triquetrum.

The volar aspect of the distal radioulnar joint was accessed in 5 of these patients to rule out a peripheral TFC tear. The DRUJ was well visualized, demonstrating an intact articular disk in 4 and a full-thickness tear with undersurface fibrillation in 1 (Fig. 7). The foveal attachment of the TFC was seen to be intact in each case (Figs. 8A, B).

COMPLICATIONS

Early in the series, one patient complained of diminished sensation over the hypothenar eminence after extended use of the 6U and VU portal for debridement of a palmar LTIL tear. Nerve conduction studies, however, were normal. There were, otherwise, no complications in the way of neurovascular or tendon injury.

REHABILITATION

The postoperative rehabilitation is dictated by the treatment of the specific pathology. Finger motion and edema control are instituted immediately. After arthroscopic debridement or an isolated wafer resection of the distal ulna, wrist range of motion exercises are instituted within 3 to 5 days postoperatively, followed by gradual strengthening. If the patient has trouble regaining supination, immobilizing the arm in supination with use of a long arm splint in between exercises is beneficial.

REFERENCES

- Slutsky DJ. Volar portals in wrist arthroscopy. *J Am Soc Surg Hand.* 2002;2:225Y232.
- Horii E, Garcia-Elias M, An KN, et al. A kinematic study of luno-triquetral dissociations. *J Hand Surg [Am].* 1991; 16:355Y362.
- Viegas SF, Patterson RM, Peterson PD, et al. Ulnar-sided perilunate instability: an anatomic and biomechanical study. *J Hand Surg [Am].* 1990;15:268Y278.
- Osterman AL, Seidman GD. The role of arthroscopy in the treatment of lunatotriquetral ligament injuries. *Hand Clin.* 1995;11:41Y50.
- Slutsky DJ. The use of a volar ulnar portal in wrist arthroscopy. *Arthroscopy.* 2004;20:158Y163.
- Stuart PR, Berger RA, Linscheid RL, et al. The dorso-palmar stability of the distal radioulnar joint. *J Hand Surg [Am].* 2000;25:689Y699.
- Haugstvedt JR, Berger RA, Berglund LJ, et al. An analysis of the constraint properties of the distal radioulnar ligament attachments to the ulna. *J Hand Surg [Am].* 2002;27:61Y67.
- Taleisnik J. The ligaments of the wrist. *J Hand Surg [Am].* 1976;1:110Y118.
- Whipple TL. Arthroscopy of the distal radioulnar joint.

- Indications, portals, and anatomy. *Hand Clin.* 1994;10:589Y592.
10. Haugstvedt JR, Berger RA, Nakamura T, et al. Relative contributions of the ulnar attachments of the triangular fibrocartilage complex to the dynamic stability of the distal radioulnar joint. *J Hand Surg [Am].* 2006;31:445Y451.
 11. Palmer AK, Werner FW. The triangular fibrocartilage complex of the wrist: anatomy and function. *J Hand Surg [Am].* 1981;6:153Y162.
 12. Ishii S, Palmer AK, Werner FW, et al. An anatomic study of the ligamentous structure of the triangular fibrocartilage complex. *J Hand Surg [Am].* 1998;23:977Y985.
 13. Adams BD, Samani JE, Holley KA. Triangular fibrocartilage injury: a laboratory model. *J Hand Surg [Am].* 1996;21:189Y193.
 14. Abrams RA, Petersen M, Botte MJ. Arthroscopic portals of the wrist: an anatomic study. *J Hand Surg [Am].* 1994;19:940Y944.
 15. Botte MJ, Cohen MS, Lavernia CJ, et al. The dorsal branch of the ulnar nerve: an anatomic study. *J Hand Surg [Am].* 1990;15:603Y607.
 16. Balogh B, Valencak J, Vesely M, et al. The nerve of Henle: an anatomic and immunohistochemical study. *J Hand Surg [Am].* 1999;24:1103Y1108.
 17. McCabe SJ, Kleinert JM. The nerve of Henle. *J Hand Surg [Am].* 1990;15:784Y788.
 18. Martin CH, Seiler JG III, Lesesne JS. The cutaneous innervation of the palm: an anatomic study of the ulnar and median nerves. *J Hand Surg [Am].* 1996;21:634Y638.
 19. Slutsky DJ. Clinical applications of volar portals in wrist arthroscopy. *Tech Hand Up Extrem Surg.* 2004;8:229Y238.
 20. Watson HK, Weinzweig J. Triquetral impingement ligament tear (tilt). *J Hand Surg [Br].* 1999;24:321Y324.
 21. Slutsky DJ. Wrist arthroscopy portals. In: Slutsky DJ, Nagel DJ, eds. *Techniques in Hand and Wrist Arthroscopy.* Philadelphia: Elsevier. In press.
 22. Slutsky DJ. Arthroscopy portals: volar and dorsal. In: Budoff J, Slade JF, Trumble TE, eds. *Master's Techniques in Wrist and Elbow Arthroscopy.* Chicago, IL: American Society for Surgery of the Hand; 2006.
 23. Tomaino MM. Ulnar impaction syndrome in the ulnar negative and neutral wrist. Diagnosis and pathoanatomy. *J Hand Surg [Br].* 1998;23:754Y757.
 24. Tomaino MM, Elfar J. Ulnar impaction syndrome. *Hand Clin.* 2005;21:567Y575.
 25. Bowers WH, WT. Arthroscopic anatomy of the wrist. In: McGinty J, ed. *Operative Arthroscopy.* New York: Raven Press; 1991:613Y623.
 26. Slutsky DJ. Wrist arthroscopy through a volar radial portal. *Arthroscopy.* 2002;18:624Y630.
 27. Berger RA. Arthroscopic anatomy of the wrist and distal radioulnar joint. *Hand Clin.* 1999;15:393Y413.vii.