

---

# ELECTROMYOGRAPHY IN HAND SURGERY

---

BY DAVID J. SLUTSKY, MD, FRCS(C)

*Hand surgeons often are called on to interpret the electrodiagnostic report, which includes both nerve conduction studies and electromyography (EMG). The EMG examination can provide useful information as to the normal and abnormal electrophysiology of muscle and its nerve. The various potentials described, however, do not point to a specific diagnosis. Through an understanding of the methodology and principles of testing the clinician will be better suited to recognizing when the report conclusions do not match the electromyographic data, or when to request further testing in cases in which insufficient data compromises one's ability to draw definitive conclusions. The indication for surgery still hinges on reproducible physical findings combined with the appropriate clinical symptoms rather than on a test abnormality.*

*Copyright © 2004 by the American Society for Surgery of the Hand*

“**T**he insertion of a needle electrode into muscle tissue with the intent of recording spontaneous activity (normal and abnormal) and voluntary motor units is perhaps the most sensitive demonstration of axonal loss.”<sup>1</sup> Hand surgeons often are called on to interpret the electrodiagnostic report, which includes both nerve conduction studies and electromyography (EMG). The key to understanding the motor unit changes in pathologic conditions lies within the muscle anatomy and the electrophysiology. Integral to interpreting the EMG report is an understanding of the terminology, meth-

odology, and pitfalls of the recording techniques. The following is the second part of a series on electrodiagnostic studies in hand surgery.<sup>2</sup> The topic is introduced by way of a short synopsis of muscle anatomy, electrophysiology, instrumentation, and recording techniques, which mostly has been excerpted from Dumitru's<sup>1</sup> publication on electrodiagnostic medicine.

## ANATOMY/ELECTROPHYSIOLOGY

### *Muscle Fiber Anatomy*

Any given muscle is composed of thousands of individual fibers or sarcomeres. A single sarcomere is a multinucleated cell surrounded by a 500-nm thick basement membrane: the sarcolemma. This membrane is similar to the nerve cell membrane in that it also consists of a lipid bilayer with hydrophobic tails forming the interior and hydrophilic heads facing outward. Transmembrane ions embedded in this bilayer serve as voltage gated channels for the passage of sodium (Na<sup>+</sup>) and potassium (K<sup>+</sup>) ions. The sarcolemma differs from the axonal membrane by forming

---

*From the South Bay Hand Surgery Center, Torrance, CA and the Department of Clinical Electrophysiology, Rocky Mountain University of Health Professions, Provo, UT.  
Address reprint requests to David J. Slutsky, MD, FRCS(C), 3475 Torrance Blvd, Suite F, Torrance, CA 90503. E-mail: d-slutsky@msn.com*

*Copyright © 2004 by the American Society for Surgery of the Hand  
1531-0914/04/0403-0008\$30.00/0  
doi:10.1016/j.jassb.2004.06.008*

an intricate intramuscular system of transverse extensions (T-tubules) that allow extracellular fluid to extend across the muscle interior.

The sarcomere contains myofibrils composed of actin and myosin filaments. The myofibrils are contractile elements, which slide past one another on exposure to calcium ( $\text{Ca}^{+2}$ ) ions. This energy-dependent process requires adenosine triphosphate, which explains the paralysis that accompanies muscle ischemia. The myofibrils are bathed in an ion-rich intracellular fluid (sarcoplasm). They are surrounded by a series of longitudinal channels (sarcoplasmic reticulum) that end in a large terminal cisterna. The T-tubules, although not directly connected, are sandwiched between the cisterna at each end of the sarcomere.

### *Electrical Activity*

The sarcolemma is a semipermeable membrane that restricts the passage of  $\text{Na}^+$ , but not  $\text{K}^+$  or chloride ions ( $\text{Cl}^-$ ). The relative concentrations of these ions results in a resting membrane potential of  $-90$  mV, similar to the nerve axon. An action potential, which is the electrical wave caused by the flow of ions, is transmitted chemically across the neuromuscular junction through the release of acetylcholine (ACh). As the axon approaches the muscle endplate, it becomes smaller and loses its myelin sheath. Depolarization of the terminal axon opens voltage-sensitive  $\text{Ca}^{+2}$  gates. The influx of  $\text{Ca}^{+2}$  results in the release of ACh. The ACh diffuses across the synaptic cleft, which takes approximately 0.1 ms. The ACh binds to receptors on the postsynaptic folds, opening the  $\text{Na}^+$  channels for 1.0 ms. If the voltage decrease exceeds the sarcolemma threshold (15 mV), the membrane is depolarized, initiating a propagating muscle action potential. The inward flow of  $\text{Na}^+$  spreads longitudinally down the muscle fiber, sequentially depolarizing each segment of the muscle membrane, similar to unmyelinated nerve. Because of the increased surface area of the T-tubules, however, it takes much longer to depolarize the sarcolemma than a comparably sized unmyelinated nerve. Conduction velocities are in the range of 3 to 5 ms versus 25 to 30 ms and the action potential duration is 5 times as long.

As the action potential spreads down the T-tubule system,  $\text{Ca}^{+2}$  is released from the sarcoplasmic reticulum of the terminal cisterna. The  $\text{Ca}^{+2}$  floods the myofibrils, resulting in a contraction lasting approximately 1/30 second. An energy-dependent pump rap-

idly sequesters the  $\text{Ca}^{+2}$  back into the sarcoplasmic reticulum, ending the contraction. If the pump fails, the contraction is maintained indefinitely (rigor mortis).

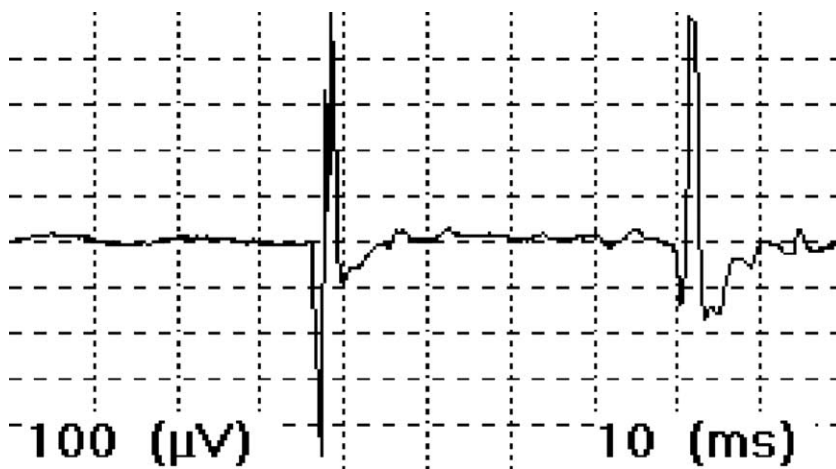
### *Motor Unit Anatomy*

The motor unit is composed of the anterior horn cell, its peripheral nerve, and multiple terminal axons, each innervating many individual muscle fibers. A skeletal muscle fascicle consists of 20 to 60 fibers surrounded by a connective tissue sheath. A single muscle fiber is innervated by only one motor unit, but there may be 2 to 3 motor units within a fascicle.<sup>3</sup> The muscle fibers of one motor unit may be distributed over 100 fascicles. They are not contiguous, but are distributed randomly over a 4- to 6-mm circumference, extending 30-mm longitudinally along the muscle itself. When the anterior horn cell fires, all of these muscle fibers depolarize. Their electrical activity summate to produce a motor unit action potential (MUAP). Up to 10 motor units may share the same oval territory. As will be shown later, this has implications with respect to the recording of denervation potentials (see section on MUAP Pathology).

## METHODOLOGY

### *Waveform Generation*

Recording electrodes detect the small voltage changes associated with the muscle action potential and convey them to an amplifier. After amplification the signal is filtered to remove any extraneous unwanted electrical activity that can distort the waveform. Newer machines change the analog signal into a binary (digital) signal through a converter. By convention, a deflection that is upward from the baseline is negative. An active electrode (E-1) is placed in an active region of the electrical field. A reference electrode (E-2) is placed over a site where the current flow is low. The signal from the reference electrode is inverted and electronically summated with the signal from E-1. This creates a referential recording, in that the recording electrode is referenced to E-2. The net result is an amplification of the differences detected from each electrode and the elimination of similar signals, which usually consist of extraneous electrical interference. A depolarization wave that propagates (ie, is moving toward the electrode) initially will produce a positive deflection. As it passes under E-1 a



**FIGURE 1.** Normal MUAPs. Each grid moving from left to right represents 10 ms. Each grid from top to bottom represents 100  $\mu\text{V}$ . The first MUAP has a duration of approximately 5 ms and an amplitude of 900  $\mu\text{V}$ .

negative deflection occurs. As the wave continues past E-1 a positive deflection is produced. A propagating wave thus appears as an initially positive, triphasic waveform. A depolarization that is directly under the electrode and does not propagate results in a monophasic negative waveform.

#### **Instrumentation**

EMG incorporates the amplified sounds of the electrical activity of muscle. The EMG equipment includes various recording, reference, and grounding electrodes, a cathode ray tube (or laptop computer), and audio speakers. Typically, E-1 consists of a needle recording electrode (monopolar or concentric) that is inserted directly into the muscle tissue, although a surface electrode may be used (surface EMG). The needle shaft is insulated with a plastic coating. The exposed needle tip (17 mm<sup>2</sup>) records the electrical activity within a 1.0- to 2.5-mm radius. Therefore, it is crucial to position the needle tip close to the muscle fibers to be examined to avoid recording artificially abnormal MUAPs (see section on Pitfalls). Needle placement is guided by both the MUAP morphology and the sound. As the needle tip moves closer to the contracting muscle fiber, the sound of the MUAP changes from dull and muffled to crisp and loud. The amplitude, duration, and morphology of the recorded MUAPs are influenced by the type of electrode, which should be specified in the EMG report. A concentric (coaxial) needle electrode consists of a steel cannula, which serves as the reference electrode, and a central 0.1-mm platinum or silver wire. Bipolar concentric needles have 2 central wires. A monopolar electrode consists of a solid, Teflon-coated, 25-gauge, steel nee-

dle. A separate surface electrode is required. When recording with monopolar electrodes the MUAPs have larger amplitudes, more turns, and more phases, but similar durations versus concentric needles. The type of electrode should remain constant throughout the testing for these reasons.

#### **MUAP Morphology**

During minimal voluntary contraction of a muscle, a correctly placed needle electrode can record the spatial summation of the electrical activity of single muscle fibers innervated by one anterior horn cell (ie, the MUAP). An action potential traveling toward and past the recording electrode produces a bi- or triphasic potential (Fig 1). MUAPs are large (300-3,000  $\mu\text{V}$ ), with 3 to 4 phases, lasting less than 12 ms. The summated voltage from all of the single muscle fibers often leads to small serrations (turns) or multiple baseline crossings (phases) in the observed waveform. MUAPs with greater than 5 phases are termed *polyphasic potentials*. Up to 30% of polyphasic MUAPs (recorded with a monopolar electrode) may be normal.<sup>4</sup> The duration increases with an increase in the number of phases and turns because it is a function of the synchrony of firing of the individual muscle fibers. The amplitude decreases exponentially from the source. There is more than a 50% decrease in the amplitude at 200  $\mu\text{m}$ . It is believed that the MUAP amplitude may arise from only 20 fibers within a 1.0-mm radius of the electrode tip.<sup>5</sup> Fibers that are farther away contribute less and may be out of phase.<sup>6</sup> Denervation potentials found in only one region of the muscle therefore may have questionable significance (see Fibrillation Potentials section).

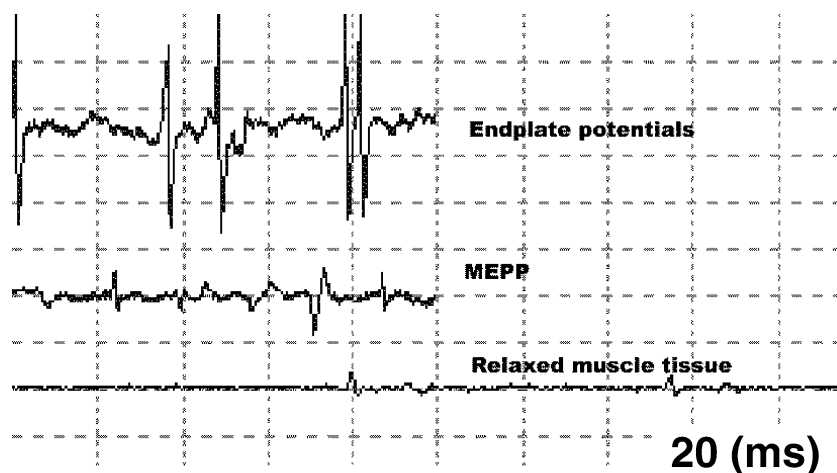


FIGURE 2. Spontaneous potentials.

### *MUAP Pathology*

A disorder that affects any component of the motor unit (ie, the anterior horn cell, its peripheral nerve, or the muscle fiber) will alter the MUAP morphology. Denervation of a muscle fiber induces axon sprouting from adjacent nerve terminals or distal nodes of Ranvier. The axon sprout reinnervates the orphaned muscle fiber, which now comes under the control of a different motor unit. Axon sprouting after nerve injury has been shown by as early as 4 days.<sup>7</sup> In animal studies, a single motor unit is capable of increasing the number of fibers it supplies by as much as 5 times.<sup>8</sup> The new axon sprouts initially are myelinated poorly and slower conducting, which results in a longer duration MUAP. The increased spatial separation of the newly added endplates prevents all of the muscle fibers from depolarizing at the same time. This asynchronous summation of the action potentials results in more phases, which increases the MUAP duration. The addition of the orphaned muscle fibers combined with atrophy of the intervening denervated fibers leads to an increase in the amplitude. Reinnervation caused by axon sprouting results in a MUAP that is larger in amplitude (more fibers), longer in duration (slower conduction), and polyphasic (asynchronous summation).

As reinnervation progresses over time, the axonal sprouts become myelinated. They conduct faster and depolarize synchronously. The large MUAPs become less polyphasic. Clinically, muscle strength returns but fine motor control does not. After reinnervation, there is a net loss of motor units even though some muscle fibers have been recaptured. In general, highly dextrous muscles, such as the first lumbrical, have

more neurons dedicated to the control of the available muscle fibers (108 muscle fibers/motor unit) as compared with large, less-dextrous muscles such as the gastrocnemius (1,934 muscle fibers/motor unit).<sup>9</sup>

### NORMAL ELECTRICAL POTENTIALS IN MUSCLE

#### *Spontaneous Activity*

In a normal muscle at rest, the isoelectric line should be silent except when the electrode is close to a neuromuscular junction. There are 2 types of spontaneous potentials that can be recorded from the endplate. When the tip of the needle rests near a muscle endplate, mechanical irritation of the nerve terminals provokes miniature endplate potentials (MEPPs). These are nonpropagating, irregular, mono- or biphasic negative waveforms of 10 to 50  $\mu\text{V}$ , that last 1 to 3 ms. They sound like a dull roar (distant ocean waves). Endplate potentials (EPPs) are thought to be caused by needle tip impalement of the endplate. They also originate from the neuromuscular junction, but are larger than MEPPs (Fig 2). They initially are negative, irregular/continuous, biphasic potentials of 100 to 300  $\mu\text{V}$ , lasting 2 to 4 ms. They have a high pitched rat-at-tat sound similar to a fibrillation.

Endplate spikes (EPSs) are short (3-5 ms), irregularly firing, initially negative (or positive), biphasic waves of 100 to 200  $\mu\text{V}$  that are thought to be subthreshold endplate action potentials from a single muscle fiber. They may be confused with positive sharp waves (which are regular and have an initial positive deflection). They most likely occur when the needle tip touches one of the small terminal branches

of an intramuscular nerve near the neuromuscular junction, which then leads to the subsequent contraction of a muscle fiber. Because the needle is usually recording from the muscle fiber and not the neuromuscular junction, the waveform may be initially positive.

MUAPs are distinguished from spontaneous potentials in that they are more regular and have slower rates. The MUAP disappears when the needle is moved slightly or the antagonist muscle is contracted. EPPs and EPS do not disappear, but their rate may slow if the needle is not moved. In a suspected denervated muscle when the electromyographer is unable to record muscle activity or a compound motor nerve action, spontaneous endplate activity would indicate that some axons are intact. In other words, neither MEPPs, EPPs, nor EPSs will be detected after denervation. If a patient is feigning paralysis, and MEPPs or EPPs are detected, the patient is malingering.

#### ABNORMAL SPONTANEOUS POTENTIALS IN MUSCLE

##### *Fibrillation Potentials*

Denervation results in muscle membrane instability, which may lead to spontaneous depolarization. The instability of the muscle fiber membrane is theorized to result from oscillations of the membrane potential, which becomes less negative until threshold is reached. Once threshold is reached, a propagating action potential is induced, which is referred to as a fibrillation potential.<sup>10</sup> These are spontaneous depolarizations of a single muscle fiber. This process regularly repeats on a time interval that is dependent on the depolarization to threshold turnaround time.<sup>11</sup> They also may be precipitated by needle movement when introduced into denervated or myopathic muscle. The regularly occurring fibrillation potentials fire in a cyclic pattern, with periods of quiescence.

Fibrillation potentials are regular, initially positive, bi- or triphasic waveforms lasting 1 to 5 ms (Fig 3). Fibrillation potentials also may fire irregularly up to 50% of the time. They fire at rates of 1 to 50 times per second (cycles/s = Hz) and have a high-pitched manual-typewriter sound. They usually are associated with axonal denervation, however, they can be found in upper-motor neuron lesion and myopathies. Fibrilla-

tions decrease as tissue becomes fibrotic, whereby all electrical activity stops. Clinically, it is not possible to determine the extent of damage solely based on the number of fibrillations.

Fibrillations potentials can be differentiated from endplate potentials in that they usually are regular and the rate of firing (1-30 Hz) usually is slower than EPPs or EPSs (2-100 Hz).

##### *Positive Sharp Waves*

The origin of positive sharp waves (PSW) and their relationship to fibrillation potentials has not been clearly identified. PSWs are thought to have the same significance as fibrillation potentials but often appear a few days earlier. They may have no significance when seen in the distal muscles of normal subjects. They also may occur after local muscle trauma.<sup>12</sup> A positive sharp wave is a monophasic, positive waveform of 100 to 1,000  $\mu$ V with a regular firing rate of 1 to 50 Hz, lasting 2 to 100 ms.

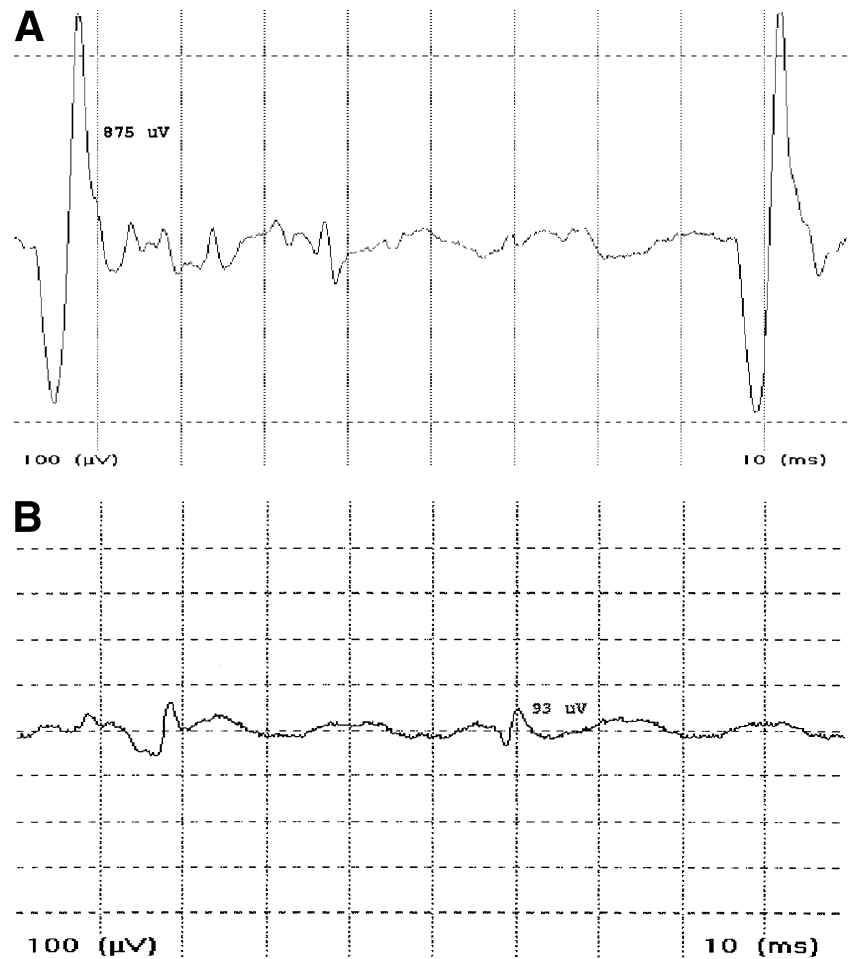
Muscle relaxation or contraction will abolish MUAPs, but will not affect abnormal spontaneous potentials. The time necessary for membrane instability is length dependent. The greater the distance between the lesion and the muscle the longer it takes. Nerve lacerations close to the endplate region may require only a few days for the onset of fibrillations/PSW versus cervical lesions, which may take weeks. This is the rationale behind waiting 10 days or more after injury to distinguish between neurapraxia versus axonotmesis/neurotmesis. Other abnormal spontaneous potentials that may be seen include complex repetitive discharges, myokemic potential, myotonic discharges, and fasciculation potentials (Table 1).

#### THE EMG EXAMINATION

**T**he EMG examination has 3 parts: (1) observing the muscle at rest, (2) insertional activity, and (3) analyzing the morphology and the recruitment of motor units at minimal to moderate voluntary muscle contraction.

##### *Muscle at Rest*

The examination starts with an observation of the muscle at rest, looking for any spontaneous electrical activity not under voluntary control. Healthy muscle is electrically silent.



**FIGURE 3.** (A) Recent denervation. The fibrillation potentials are of large amplitude. (B) Chronic denervation. Note the small amplitude fibrillation potentials.

### *Insertional Activity*

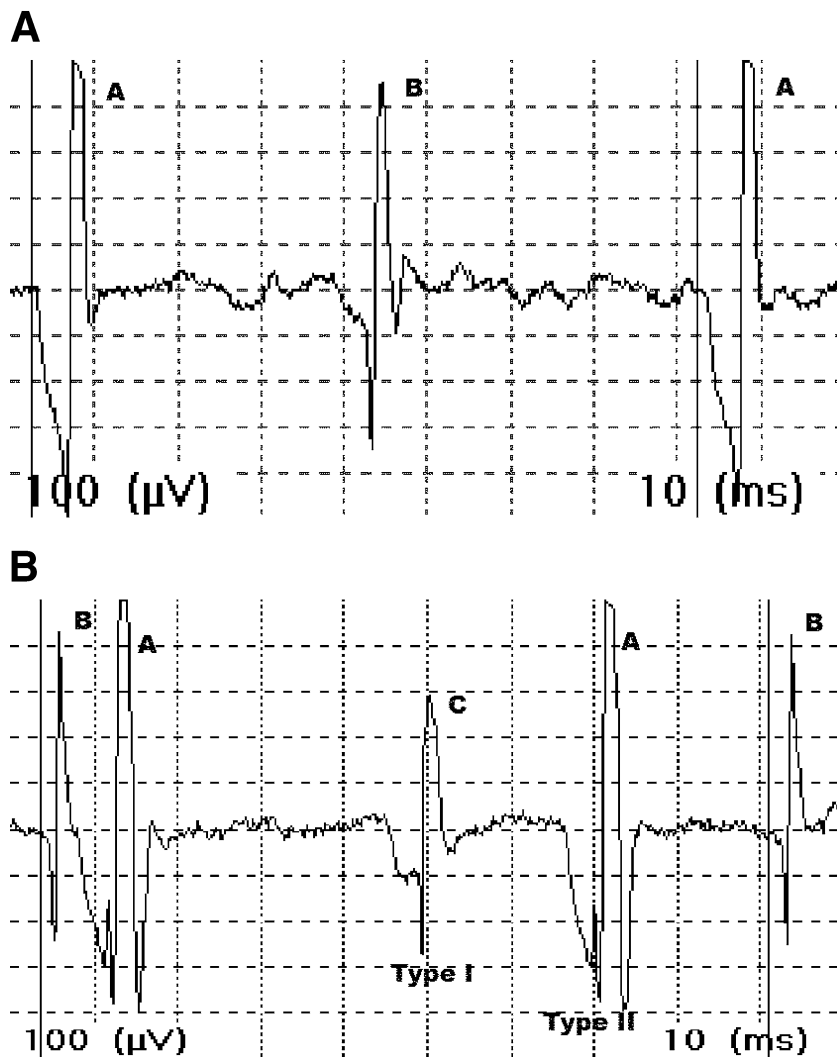
A needle is advanced sequentially into the muscle to 3 successive depths. The needle then is withdrawn and redirected along a different line at 4 regions of the muscle, for a total of 12 sampling sites. Insertion of a needle electrode mechanically depolarizes muscle tis-

sue. With normal insertional activity, the muscle produces brief bursts of high-frequency positive and negative spikes that sound somewhat similar to static.<sup>13</sup> The activity stops after cessation of needle movement. Increased insertional activity is present if the electrical activity persists >230 ms for monopolar

**TABLE 1**

#### **Abnormal Spontaneous Potentials**

Abnormal Potential	Description	Conditions
Complex repetitive discharge	Runs of regular spike patterns, abrupt onset, and cessation	Myopathies, neuropathies, normal muscle
Myotonic discharge	Brief positive spikes that wax and wane	Myopathies, peripheral neuropathy
Fasciculations	Irregular, normal, or complex MUAP	Exercise induced, lower motor neuron disorders, peripheral/metabolic neuropathy
Myokemic discharges	Regular persistent firing of normal MUAPs/occasional abrupt cessation	Chronic nerve compression, radiculopathy, multiple sclerosis



**FIGURE 4.** (A) Normal recruitment. Motor unit A fires every 80 ms (8 grids at 10 ms/grid). The firing rate thus is  $1,000/80 = 12.5$  cycles/s (Hz). As the MUAP (letter A within Fig 4A) starts firing  $>10$  Hz, a second MUAP (letter B within Fig 4A) is recruited. The recruitment ratio (RR) is  $12.5/2 = 6.25$ . (B) Normal recruitment. The RR for fastest firing MUAP (letter A within Fig 4B) is  $1,000/60 = 16.6$  Hz. According to the rule of 5's there should be 3 different MUAPs on the screen. Both type I and type II MUAPs are firing. The RR is 5.5.

needle electrode insertion and  $>300$  ms for concentric needles. The needle also may provoke transient or sustained fibrillation potentials or PSWs before they are seen at rest. This is often but not invariably a sign of membrane instability. Decreased insertional activity occurs in myopathies and when muscle tissue is ischemic or has undergone fibrosis and is no longer capable of electrical activity.

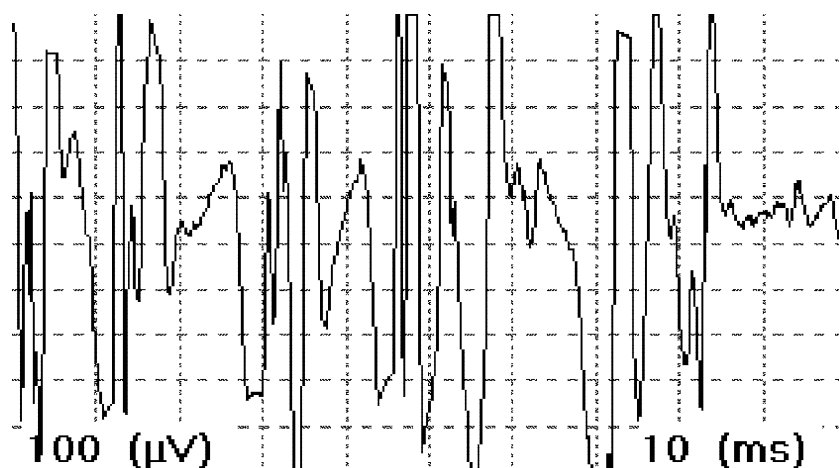
#### *Minimal to Moderate Voluntary Contraction*

The muscle is examined during submaximal contraction to observe the MUAP morphology. Because MUAP amplitude varies with respect to the distance between the recording electrode and the muscle fiber, the MUAP should be analyzed only when the needle electrode is close to the muscle fiber under examination. A nearby MUAP sounds crisp and loud and has

a short rise time, whereas a distant MUAP sounds like a muffled thud and has a long rise time. In general, 20 different MUAPs are analyzed for amplitude, duration, and phases.

Recruitment is the successive activation of motor units with increasing strength of muscle contraction. Minimal muscular effort results in the repetitive firing of 1 to 2 motor units, which are low-amplitude, slow-twitch (type I) muscle fibers.<sup>14</sup> With stronger effort, the already activated motor units must fire more rapidly to maintain the strength of contraction. New high-amplitude, fast-twitch motor units (type II) then are recruited (Fig 4). With maximum contraction, many rapidly firing motor units ultimately run together, interfering with the recognition of individual MUAPs (ie, a full interference pattern) (Fig

**FIGURE 5.** Full interference pattern. The baseline is obliterated completely by the MUAPs.



5). Generally, after 1 MUAP fires at a rate of 10 times per second, a second MUAP is recruited (Fig 4A). The recruitment ratio is the frequency of the fastest firing MUAP divided by the number of different MUAPs seen. A normal recruitment ratio is close to 5.<sup>15</sup> For example, if the fastest MUAP is firing 15 times per second, there should be 3 different MUAPs on the screen (Fig 4B).

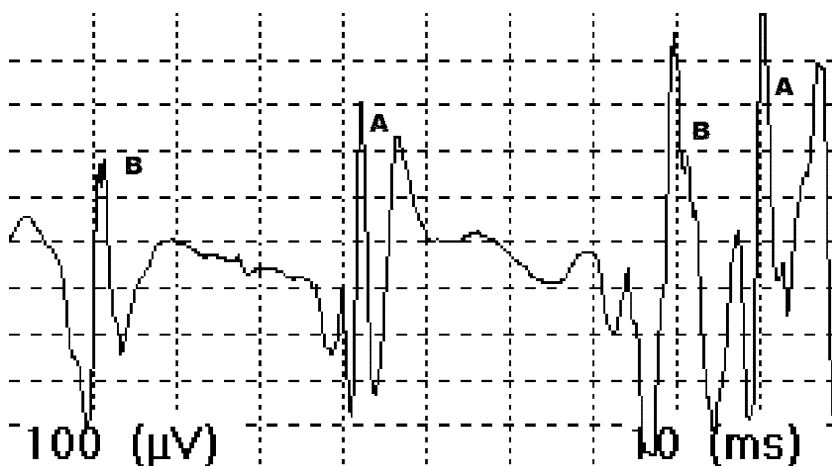
In neurogenic disorders, there are fewer viable motor units, but there is no change in the number of muscle fibers. The remaining motor units must fire faster in an attempt to maintain the force of contraction. One observes too few MUAPs firing very rapidly, leading to decreased recruitment (Fig 6). In myopathies the number of motor units is unchanged, but each motor unit contains fewer muscle fibers. Because the patient feels weaker, they try to compensate by stimulating the remaining motor units to fire earlier and faster. One observes

more MUAPs firing at a faster rate, resulting in increased recruitment.

#### CLASSIFICATION OF NERVE INJURY

##### *Neurapraxia*

The nerve connective tissue remains intact, but there is an area of demyelination that allows current leakage. The blocked nerve conduction prevents muscle fiber depolarization, which simulates axonal loss. Although there may be a sensory and motor loss, the nerve distal to the lesion conducts normally. There is no axonal loss and no Wallerian degeneration has occurred. The most apparent finding on the EMG is decrease recruitment, caused by a reduced number of motor unit potentials firing more rapidly than normal. The clinical correlate is that of muscle weakness without denervation, but fibrillation potentials may occasionally be seen.<sup>16</sup>



**FIGURE 6.** Decreased recruitment. MUAP (letter A within Fig 6) is firing at 16.6 Hz. There should be 3 different MUAPs on the screen, but there are only 2. The RR is 8.3.



TABLE 2

## Fibrillation Grading Scale

Fibrillation Potentials	Grade
Absent	0
Persist >1 s in 2 areas	1+
Persist >1 s in 3 or more areas	2+
Intermittent in all areas	3+
Continuous in all areas	4+

Reprinted with permission from Daube.<sup>18</sup>

*Axonotmesis/Neurotmesis*

The axons are disrupted but the surrounding stroma is intact. This cannot initially be distinguished initially from neurotmesis until sufficient time has passed for Wallerian degeneration to occur. Although it is dependent on the length of the distal nerve stump, Wallerian degeneration typically occurs by 10 to 14 days.<sup>17</sup> Positive sharp waves may predate fibrillation potentials by 2 to 3 days.<sup>12</sup>

Fibrillation potentials and positive sharp waves are graded on a scale of 1 to 4<sup>18</sup> (Table 2). This is an ordinal (density) scale rather than a ratio scale. In other words, 4+ fibrillations are not twice as bad as 2+.<sup>19</sup> The presence of 4+ fibrillation potentials does not by itself indicate that the entire muscle is denervated, but rather only a specific region of the muscle surrounding the needle electrode. One must look for MUAPs and examine multiple areas of the muscle before concluding that it is denervated completely. In addition, comparison of fibrillation numbers from one examination with another is not reliable.<sup>20</sup> Axon loss is better evaluated by looking for a loss of recruitment on EMG testing, and a decrease

in the amplitude of the distal compound motor action potential during the nerve conduction study (Fig 7).

Fibrillations decrease in number as reinnervation progresses. This also occurs in complete lesions as the number of viable muscle fibers diminishes. In this case, a reduction in the number of fibrillation potentials represents muscle fibrosis rather than recovery. Fibrillations also may occur after direct muscle injury. This can make it difficult to localize a coexisting nerve lesion, such as a radial nerve palsy after a humeral fracture.<sup>21</sup> The amplitude of the fibrillation potentials can be used to estimate the duration of the pathology because it decreases with time. They may be 1,000  $\mu\text{V}$  in acute conditions, but it is rare to find any larger than 100  $\mu\text{V}$  after 12 months (Fig 3A and 3B).<sup>22</sup>

*Partial Lesions*

Partial lesions usually represent axonotmesis, in which recovery depends on axonal sprouting and regeneration. With an incomplete axonal injury, loss of motor units results in reduced recruitment. As axonal sprouting occurs, innervation of noncontiguous muscle fibers results in increased waveform duration, polyphasia, and an increased MUAP amplitude (Fig 8). With time the polyphasia diminishes but the increased amplitudes remain. There may be a biphasic pattern of recovery owing to early axonal sprouting followed by late end organ reinnervation.

*Complete Lesions*

When the nerve is divided completely, recovery is dependent solely on axonal regeneration. The EMG is initially silent, followed by the appearance of small, long duration, unstable, and polyphasic nascent po-

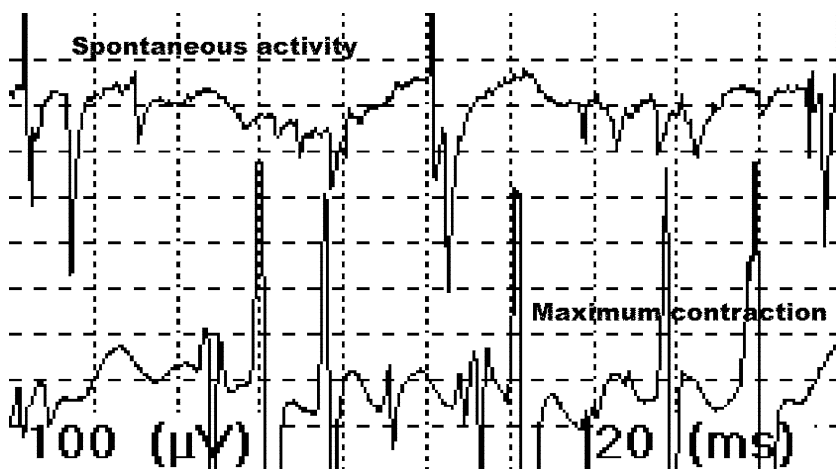
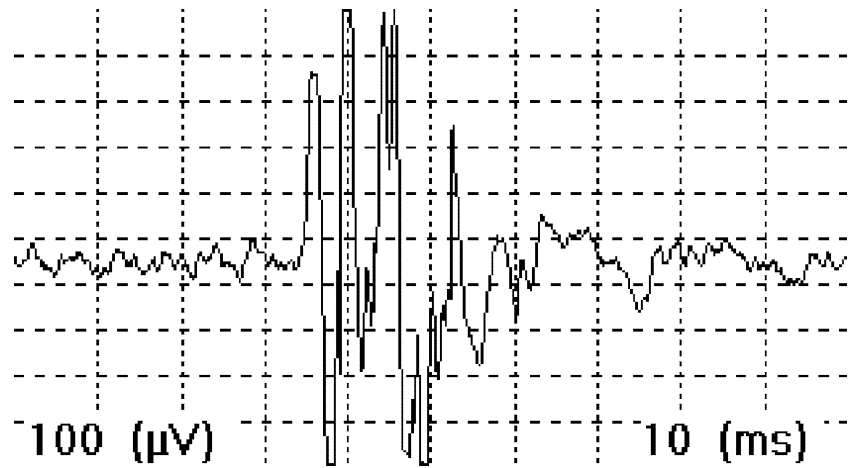


FIGURE 7. Partial ulnar nerve injury at 3 months. The top tracing shows trains of PSWs obliterating the baseline (4+). The bottom tracing shows only 1 rapidly firing MUAP at maximum contraction, which reflects a loss of motor units. There is no polyphasia, indicating an absence of axonal sprouting (reinnervation).

FIGURE 8. Polyphasic MUAP.



tentials (Fig 9). They usually precede the onset of clinically evident voluntary movement.<sup>20</sup> It has been recommended to wait 2 to 4 months and look for evidence of reinnervation in previously completely denervated muscles.<sup>23</sup> Lesions that have spontaneous recovery are treated nonsurgically, whereas those without recovery are explored. As a general rule, nerve regrowth occurs at approximately 1 inch per month. Motor endplates degrade at about 1% per week, hence the maximum length that a nerve can grow to restore motor function is approximately 13 to 18 inches. Repairs at the brachial plexus level rarely result in the recovery of any intrinsic muscle function. Sensory end organs, however, remain viable and can be reinnervated even after many years.

#### *Radiculopathy*

A myotome consists of all of the muscles of a limb that are innervated by a specific nerve root level.

Because of the multilevel innervation of limb muscles, each muscle belongs to more than one myotome. Anterior (efferent) and posterior (afferent) nerve roots arising from the spinal cord fuse to form the spinal nerve, which in turn divide into the anterior and posterior primary rami. It is necessary to examine at least 2 to 3 muscles per myotome in both the anterior and posterior primary rami distribution. Efferent motor fibers from the anterior cervical rami fuse to form the brachial plexus. Afferent sensory fibers from the posterior root fuse to form the dorsal root ganglion outside the neural foramen, where the sensory nerve cell bodies reside. Nerve root compression may result in subjective sensory abnormalities, although the sensory nerve action potentials will remain normal. This is because the distal sensory nerve axons remain connected to healthy cell bodies in the dorsal root ganglion, which are distal to the lesion at the foraminal

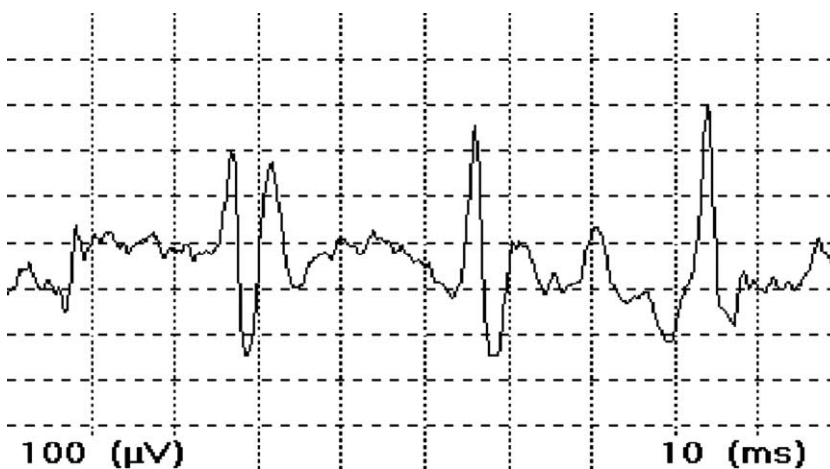


FIGURE 9. Early reinnervation of the first dorsal interosseus after nerve repair.

**Table 3**  
**Sequential Changes in Radicular Lesions**

	<1 Week	1-3 Months	>3 Months
SNAP	Normal	Normal	Normal
CMAP	Normal	Reduced	Reduced
Fibrillations	Absent	>300 $\mu$ V,	<100 $\mu$ V,
PSW		occurs in proximal muscles (7 d) followed by distal muscles (3-5 wk)	decreased numbers
MUAPs	Reduced recruitment	Reduced recruitment	Reduced recruitment

Abbreviation: CMAP, compound muscle action potential.

level. Cell bodies of the motor fibers are located in the ventral horn of the spinal cord. Radicular lesions thus lead to a loss of motor axons and Wallerian degeneration, with the subsequent appearance of fibrillation potentials and PSWs (Table 3). In a C6 lesion, for example, denervation potentials may be seen in the biceps, extensor carpi radialis, and pronator teres, but not the triceps, abductor pollicis brevis, or first dorsal interosseous muscles. For uncertain reasons, EMG abnormalities may be seen occasionally in only 1 to 2 limb muscles. It is not uncommon for patients to have both a C6-7 cervical radiculopathy and carpal tunnel compression, or a C8-T1 radiculopathy and cubital tunnel syndrome. A nerve conduction study likewise should be performed.

### Paraspinal EMG

If abnormalities are noted in the paraspinal muscles, the lesion must be as far proximal as the root level because both the anterior and posterior 1° rami are affected. Approximately 25% to 40% of patients with a radiculopathy may show fibrillation potentials only in the paraspinal muscles.<sup>24</sup> Radiculopathies are only one cause of paraspinal abnormalities because any disorder of the anterior horn cell, posterior rami, or the muscle fibers themselves can produce membrane instability such as motor neuron disease, myopathies, diabetes, and so forth.

An axonal lesion distal to the origin of the posterior primary ramus, such as a brachial plexus lesion, should not affect the paraspinals. Because the plexus is distal to the dorsal root ganglion, the sensory nerve

action potential (SNAP) amplitudes should be decreased in addition to the EMG findings of axonal loss.

### PITFALLS

#### False Positive

**Insufficient muscles examined.** Radicular injuries are diagnosed not only by documenting abnormalities in a particular myotome, but by showing a distinct lack of abnormalities in other myotomes, especially of the opposite limb.

**Misidentification of normal potentials.** EPSs that fire irregularly at high rates may be mistaken for fibrillation potentials, which fire regularly at slower rates.

**Overinterpretation of normal variants.** Trains of PSWs may last longer than anticipated after needle insertion or movement, which is a normal variant and is not diagnostic of any nerve or muscle disorder.<sup>25</sup>

**MUAP overlap.** MUAPs that run together may appear polyphasic and of increased duration (Fig 10). This can be minimized by using a trigger and delay line on the EMG trace to ensure that the same MUAP is being examined.

#### False Negative

**Time of study.** Generally, the peak of fibrillations and PSWs is 2 to 4 weeks. An examination performed within the first 7 to 10 days may be falsely negative.

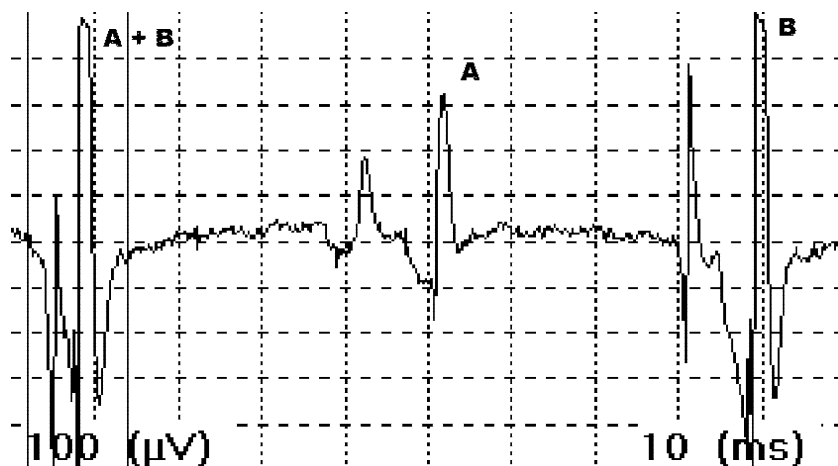**Temperature.** Decreased temperature suppresses the firing rates and the number of fibrillations and PSWs.

**Instrumentation defects.** Defective EMG needles may lead to faulty recordings.

**MUAP parameters.** MUAP amplitude varies with respect to the distance between the recording electrode and the muscle fiber. A MUAP should be analyzed only when the distance between the needle electrode and the muscle tissue is optimal so that the needle is close to the fiber that it is recording. The MUAP sound should be crisp and loud, otherwise error may be introduced in measuring the amplitude, duration, and phases.

**Polyphasia.** Polyphasic potentials are only of diagnostic value when quantified with a trigger line by examining at least 20 individual MUAPs and then calculating the percent of polyphasic potentials. An increase in polyphasic potentials only implies that at some point

**FIGURE 10.** Pseudopolyphasia MUAP (letters A and B within Fig 10) and run together, producing an artificially polyphasic MUAP.



the motor unit has undergone remodeling. This is not by itself diagnostic of any specific disease or time of occurrence. All persons have some degree of polyphasic potentials.

**Recruitment.** Recruitment abnormalities are not especially sensitive and rarely aid in the diagnosis unless accompanied by fibrillation potentials, PSWs, and MUAP duration changes. It can be difficult for some patients to recruit only a single motor unit even during minimal voluntary contraction. Distal muscles are more prone to false-positive results.

**Interference pattern.** An interference pattern is not equivalent to recruitment. It rarely provides any information and can be the subject of false-positive results caused by lack of patient cooperation, pain, or needle placement too distant from the muscle tissue.

**Age.** It is thought that there is a gradual loss of anterior horn cells with age.<sup>26</sup> This subclinical muscle denervation induces collateral sprouting to remodel the remaining motor units. The increase in the number of muscle fibers per motor unit results in an

increase of the MUAP duration and amplitude with age, which can be interpreted falsely as a neurogenic lesion.

#### SUMMARY

More so than nerve conduction studies, EMG is an art form honed through practice and experience. The EMG examination can provide useful information as to the normal and abnormal electrophysiology of muscle and its nerve. The various potentials described, however, do not point to a specific diagnosis. The test results should not be taken out of context. Through an understanding of the methodology and principles of testing the clinician will be better suited to recognizing when the report conclusions do not match the EMG data, or when to request further testing in cases in which insufficient data compromises one's ability to draw definitive conclusions. The indication for surgery still hinges on reproducible physical findings combined with the appropriate clinical symptoms rather than on a test abnormality.

#### REFERENCES

1. Dumitru D. *Electrodiagnostic medicine*. Philadelphia: Hanley and Belfus, Inc., 1995:47-584.
2. Slutsky DJ. Nerve conduction studies in hand surgery. *J Am Soc Surg Hand* 2002;3:1-18.
3. Buchthal F, Schmalbruch H. Motor unit of mammalian muscle. *Physiol Rev* 1980;60:90-142.
4. Chu J, Bruyninckx F, Chan RC. Significance of motor unit action potential parameters in normal and neurogenic situations. *Electromyogr Clin Neurophysiol* 1986;26:465-479.
5. Brumback RA, Bobele GB, Rayan GM. Electrodiagnosis of compressive nerve lesions. *Hand Clin* 1992;8:241-254.
6. Thiele B, Bohle A. [Number of spike-components contributing to the motor unit potential (author's translation)]. *EEG EMG Z Elektroenzephalogr Elektromyogr Verwandte Geb* 1978;9:125-130.
7. Miller RG. AAEE minimonograph #28: injury to peripheral motor nerves. *Muscle Nerve* 1987;10:698-710.
8. Brown MC, Ironton R. Sprouting and regression of neuromuscular synapses in partially denervated mammalian muscles. *J Physiol* 1978;278:325-348.
9. Feinstein B, Lindegard B, Nyman E, Wohlfart G. Morphologic studies of motor units in normal human muscles. *Acta Anat (Basel)* 1955;23:127-142.
10. Buchthal F, Rosenfalck P. Spontaneous electrical activity of

- human muscle. *Electroencephalogr Clin Neurophysiol* 1966;20:321-336.
11. Thesleff S, Ward MR. Studies on the mechanism of fibrillation potentials in denervated muscle. *J Physiol* 1975;244:313-323.
  12. Kraft GH. Are fibrillation potentials and positive sharp waves the same? No. *Muscle Nerve* 1996;19:216-220.
  13. Wiechers D, Stow R, Johnson EW. Electromyographic insertional activity mechanically provoked in the biceps brachii. *Arch Phys Med Rehabil* 1977;58:573-578.
  14. Warmolts JR, Engel WK. Open-biopsy electromyography. I. Correlation of motor unit behavior with histochemical muscle fiber type in human limb muscle. *Arch Neurol* 1972;27:512-517.
  15. Petajan JH. AAEM minimonograph #3: motor unit recruitment. *Muscle Nerve* 1991;14:489-502.
  16. Trojaborg W. Early electrophysiologic changes in conduction block. *Muscle Nerve* 1978;1:400-403.
  17. Chaudhry V, Cornblath DR. Wallerian degeneration in human nerves: serial electrophysiological studies. *Muscle Nerve* 1992;15:687-693.
  18. Daube JR. AAEM minimonograph #11: needle examination in clinical electromyography. *Muscle Nerve* 1991;14:685-700.
  19. Carter GT, Robinson LR, Chang VH, Kraft GH. Electrodagnostic evaluation of traumatic nerve injuries. *Hand Clin* 2000;16:1-12, vii
  20. Dorfman LJ. Quantitative clinical electrophysiology in the evaluation of nerve injury and regeneration. *Muscle Nerve* 1990;13:822-828.
  21. Partanen JV, Danner R. Fibrillation potentials after muscle injury in humans. *Muscle Nerve* 1982;5:S70-S73.
  22. Kraft GH. Fibrillation potential amplitude and muscle atrophy following peripheral nerve injury. *Muscle Nerve* 1990;13:814-821.
  23. Kline DG. Surgical repair of peripheral nerve injury. *Muscle Nerve* 1990;13:843-852.
  24. Johnson EW, Melvin JL. Value of electromyography in lumbar radiculopathy. *Arch Phys Med Rehabil* 1971;52:239-243.
  25. Wiechers DO. Electromyographic insertional activity in normal limb muscles. *Arch Phys Med Rehabil* 1979;60:359-363.
  26. Brown WF. Functional compensation of human motor units in health and disease. *J Neurol Sci* 1973;20:199-209.
-