

CHAPTER 12

Wrist Arthroscopy: Portals and Procedures

David J. Slutsky, MD, FRCS[C]

Introduction

Wrist arthroscopy is currently the most accurate tool for the diagnosis of intra-articular pathology of the wrist. In addition, it allows for minimally invasive treatment of many disorders.

I. Portals

The traditional portals for wrist arthroscopy are dorsal. This is in part due to the relative lack of neurovascular structures on the dorsum of the wrist as well as the initial emphasis on assessing the volar wrist ligaments.

Table 1 describes the typical fields of view as seen through a 2.7 mm arthroscope under ideal conditions through the various wrist arthroscopy portals. Synovitis, fractures, ligament tears and a tight wrist joint may limit the field of view which necessitates the use of more portals to adequately assess the entire wrist.

Dorsal radiocarpal portals

The dorsal radiocarpal portals are named for the dorsal extensor compartments they are between. For example, the 1-2 portal lies between the 1st and 2nd extensor compartments, the 3-4 portal lies between the 3rd and 4th extensor compartments and the 4-5 portal lies between the 4th and 5th compartments. The 6R portal is located on the radial side of the extensor carpi ulnaris (ECU) tendon and the 6U portal is located on the ulnar side of the ECU (Figure 1A-C). The 3-4 and 4-5 portals are the main portals used for radiocarpal arthroscopy, with the 6R portal providing further access to the ulnar aspect of this joint. The 6U portal is typically used for outflow via an 18-gauge needle.

The 3-4 portal is located in the concavity between the EPL and the EDC, just distal to Lister's tubercle, in line with the 2nd webspace. The radiocarpal joint is identified

with a 22-gauge needle angled 10° volarly to account for the inclination of the distal radius. A shallow incision is made to avoid injuring small branches of the SRN and superficial veins. Tenotomy scissors or blunt forceps are used to spread the soft tissue and pierce the dorsal capsule.

The interval for the 4-5 portal is identified with the 22-gauge needle between the EDC and EDM, in line with the ring metacarpal. Due to the radial inclination of the distal radius, this portal lies slightly proximal and about 1 cm ulnar to the 3-4 portal.

The 6R portal is identified on the radial side of the ECU tendon, just distal to the ulnar head. The scope should be angled 10° proximally to avoid hitting the triquetrum. The 6U portal is found on the ulnar side of the ECU tendon. Angling the needle distally and ulnarly deviating of the wrist helps avoid running into the triquetrum.

The relevant landmarks for the 1-2 portal in the snuff box are palpated and outlined. These include the distal edge of the radial styloid, the abductor pollicis longus (APL), extensor pollicis brevis (EPB) and extensor pollicis longus (EPL) tendons, and the radial artery in the snuff box (Figure 2). In order to minimize the risk of injury to branches of the superficial radial nerve and the radial artery, the 1-2 portal should be placed more volar and proximal in the snuffbox (Figure 3A-C). The entry site is outlined no more than 4.5 mm dorsal to the 1st extensor compartment and within 4.5 mm of the radial styloid. A 22-gauge needle is used to identify the joint space, followed by a small superficial skin incision. The tissue is spread down to the capsule which is pierced by tenotomy scissors. A cannula and blunt trocar are inserted with the wrist in ulnar deviation to minimize damage to the proximal scaphoid.

Volar radiocarpal portals

The clinical utility of volar portals has recently been elucidated. Volar portals allow for the visualization of the dorsal capsular structures as well as the volar aspects of the intrinsic carpal ligaments.

Hand Surgery Update

Wrist Arthroscopy: Portals and Procedures

Table 1. Field of View

Portal	Radial	Central	Volar	Dorsal /Distal	Ulnar
1-2 Portal	scaphoid and lunate fossa, dorsal rim of radius.	proximal and radial scaphoid, proximal lunate	oblique views of RSC, LRL,SRL	oblique views of DRCL	TFCC poorly visualized
3-4 Portal	scaphoid and lunate fossa, volar rim of radius	proximal scaphoid and lunate, dorsal and membranous SLIL	RSC, RSL, LRL, ULL	oblique views of the DRCL insertion onto the dorsal SLIL	TFCC radial insertion, central disc, ulnar attachment, PRUL, DRUL, PSO, PTR
4-5 Portal	lunate fossa, volar rim of radius	proximal lunate, triquetrum, dorsal and membranous LTIL	RSL, LRL, ULL	poorly seen	TFCC radial insertion, central disc, ulnar attachment, PRUL, DRUL, PSO, PTR
6R Portal	poorly seen	proximal lunate, triquetrum, dorsal and membranous LTIL	ULL, ULT	poorly seen	TFCC radial insertion, central disc, ulnar attachment, PRUL, DRUL, PSO, PTR
6U Portal	sigmoid notch	proximal triquetrum, membranous LTIL	oblique views of ULL, ULT	oblique views of DRCL	TFCC oblique views of the radial insertion, central disc, ulnar attachment, PRUL, DRUL
VR Portal	scaphoid and lunate fossa, dorsal rim of radius	scaphoid and lunate fossa, dorsal rim of radius	palmar scaphoid and lunate, palmar SLIL	oblique views of RSL, LRL ULL	oblique views of the radial insertion, central disc, ulnar attachment, PRUL DRUL
Midcarpal Radial Portal	STT joint, distal scaphoid pole	SLIL joint, distal scaphoid, distal lunate	radial limb of arcuate ligament, i.e., continuation of the RSC ligament	proximal capitate, CHIL, oblique views of proximal hamate	LTIL joint, partial triquetrum
Midcarpal Ulnar Portal	distal articular surface of the lunate and triquetrum and partial scaphoid	SLIL joint	volar limb of arcuate ligament i.e. continuation of the triquetro-capito-lunate	oblique views of proximal capitate, CHIL, proximal hamate	LTIL joint, triquetrum
Dorsal DRUJ Portals	sigmoid notch, radial attachment of TFCC	Ulnar head	palmar radioulnar ligament	proximal surface of articular disc	limited view of deep DRUL
Volar DRUJ Portal	sigmoid notch, radial attachment of TFCC	Ulnar head	dorsal radioulnar ligament	proximal surface of articular disc	foveal attachment of deep fibers of TFCC, i.e., DRUL, PRUL

RSC = radioscapocapitate ligament
 RSL = radioscapohunate ligament
 LRL = long radiolunate ligament
 SRL = short radiolunate ligament
 DRCL = radiocarpal ligament

SLIL = scapholunate interosseous ligament
 LTIL = lunotriquetral interosseous ligament
 TFCC = triangular fibrocartilage
 ULL = ulnolunate ligament
 ULT = ulnotriquetral ligament

PRUL = palmar radioulnar ligament
 DRUL = dorsal radioulnar ligament
 PSR = prestyloid recess
 PTO = piso-triquetral orifice
 CHIL = capitolunate ligament

Adapted from Slutsky DJ. Wrist Arthroscopy Portals. In *Techniques in Hand and Wrist Arthroscopy*. Slutsky DJ, Nagle DJ, eds. Philadelphia: Elsevier, Inc. In press.

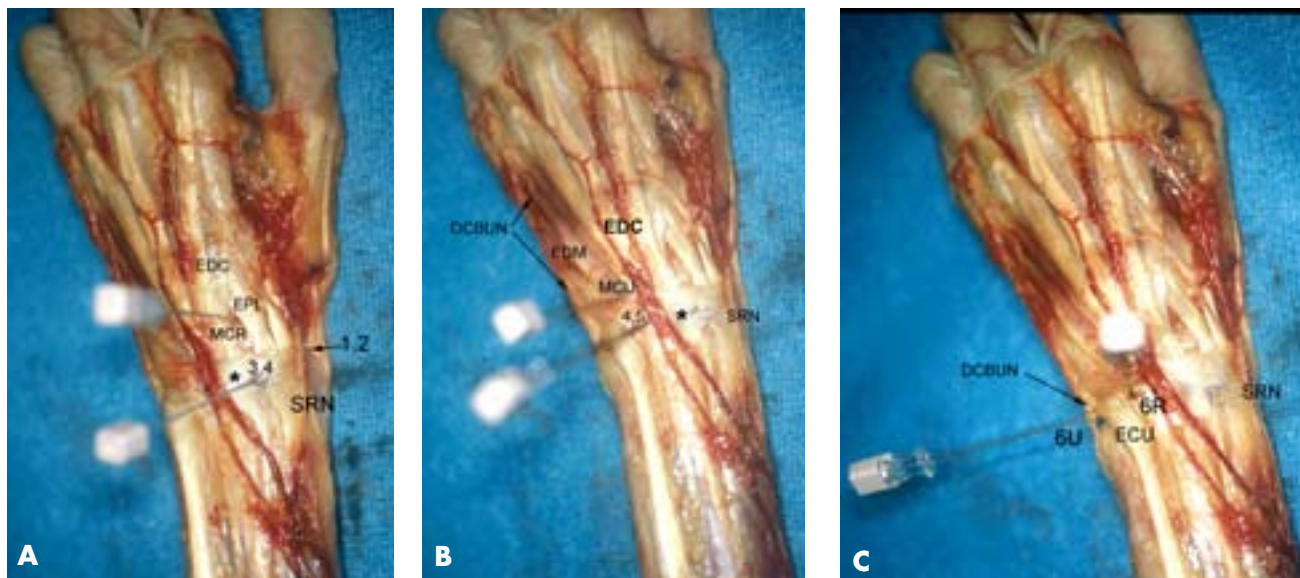


Figure 1.

Dorsal Portal Anatomy. **A)** Cadaver dissection of the dorsal aspect of a left wrist demonstrating the relative positions of the dorsoradial portals. EDC = extensor digitorum communis. EPL = extensor pollicis longus, SRN = superficial radial nerve. Lister's tubercle = *. **B)** Relative positions of the dorsoulnar portals. EDM = extensor digiti minimi, DCBUN = dorsal cutaneous branch of the ulnar nerve. **C)** Positions of the 6R and 6U portals. From Slutsky DJ. Wrist Arthroscopy Portals. In *Techniques in Hand and Wrist Arthroscopy*. Slutsky DJ, Nagle DJ, eds. Philadelphia: Elsevier, Inc. In press.

The volar radial (VR) portal allows for evaluation of the dorsal radiocarpal ligament (DRCL) and the volar subregion of the scapholunate interosseous ligament (SLIL). The VR portal also facilitates arthroscopic reduction of intra-articular fractures of the distal radius fractures by providing a clear view of the dorsal rim fragments.

A 2 cm transverse or longitudinal incision is made in the proximal wrist crease overlying the flexor carpi radialis (FCR) tendon. It is not necessary to specifically identify the adjacent neurovascular structures, provided that the anatomical landmarks are adhered to. The tendon sheath is entered and the FCR tendon is retracted ulnarly to protect the palmar cutaneous branch of the median nerve. The radiocarpal joint space is identified with a 22-gauge needle and distended with 5 cc of saline. Blunt tenotomy scissors or forceps are used to pierce the volar capsule, usually between the radioscapo-capitate ligament (RSC) and the long radiolunate ligament (LRL) (Figure 4). A blunt trochar is then introduced, followed by a 2.7 mm arthroscope (Figure 5A-C).

The median nerve lies 8 mm (6–10 mm) ulnar to the VR portal while the palmar cutaneous branch passes 4 mm (3–5 mm) ulnar to the portal, but always lies to the ulnar side of the

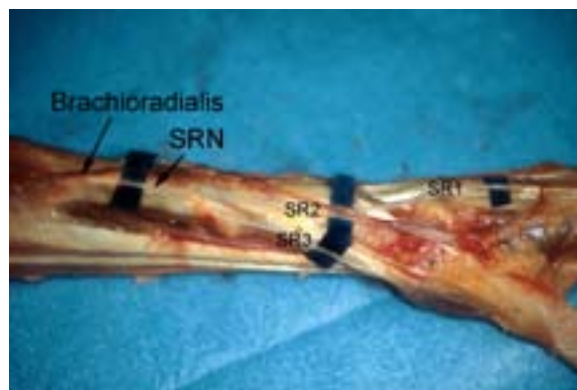


Figure 2.

Branches of the Superficial Radial Nerve (SRN). SR1 = minor dorsal branch, SR2 = major dorsal branch, SR3 = major palmar branch. From Slutsky DJ. Wrist Arthroscopy Portals. In *Techniques in Hand and Wrist Arthroscopy*. Slutsky DJ, Nagle DJ, eds. Philadelphia: Elsevier, Inc. In press.

FCR. The radial artery lies 5.8 mm (4–6 mm) radial to the portal and its superficial palmar branch is located 10.6 mm (6–16 mm) distal to the portal. There is a safe zone compris-

Wrist Arthroscopy: Portals and Procedures

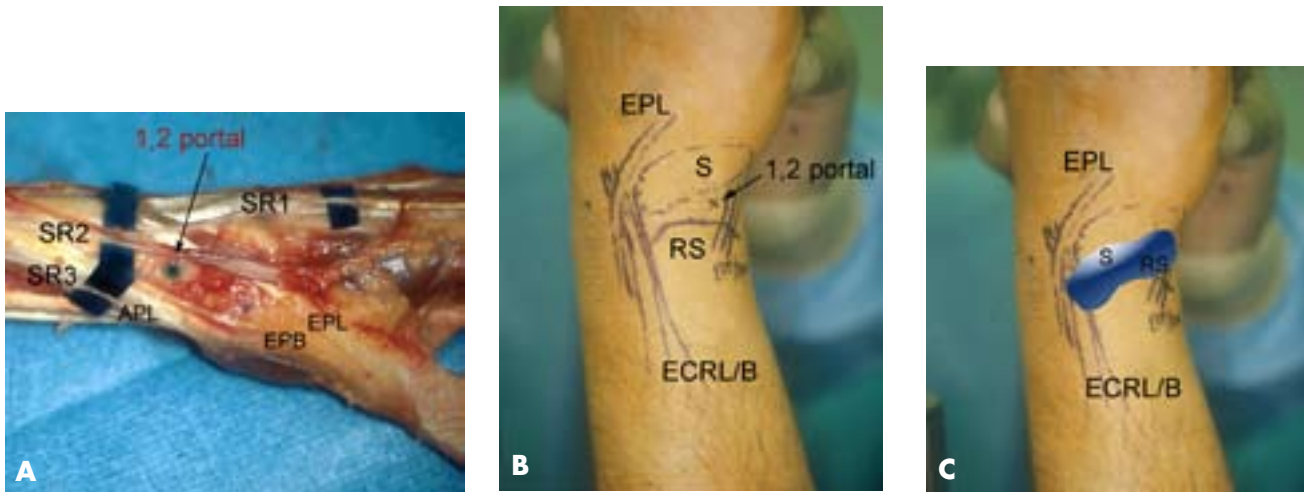


Figure 3.

Landmarks for the 1-2 portal. **A)** Cadaver dissection demonstrating the placement of the 1-2 portal. SR = superficial radial nerve branches, EPL = extensor pollicis longus, EPB = extensor pollicis brevis, APL = abductor pollicis longus. **B)** Surface landmarks for 1-2 portal. S = scaphoid, ECRL/B = extensor carpi radialis longus and brevis. **C)** Superimposed intra-articular field of view. From Slutsky DJ. Wrist Arthroscopy Portals. In *Techniques in Hand and Wrist Arthroscopy*. Slutsky DJ, Nagle DJ, eds. Philadelphia: Elsevier, Inc. In press.

ing the width of the FCR tendon plus at least 3 mm or more in all directions that is free of neurovascular structures.

The volar ulnar (VU) portal is more technically demanding to establish, but it provides unparalleled views of the dorsal radioulnar ligament (DRUL) and the dorsal ulnar wrist capsule, which contains the extensor carpi ulnaris subsheath (ECUS). It is especially useful for visualizing and debriding volar tears of the lunotriquetral ligament (Figure 6). It also aids in the repair or debridement of dorsal TFC tears, since the proximity of the 4-5 and 6R portals makes triangulation of instruments in this region difficult (Figure 7).

The volar ulnar portal is established via a 2 cm longitudinal incision centered over the proximal wrist crease along the ulnar edge of the finger flexor tendons (Figure 8A–C). Careful dissection and wound spread technique should be observed in order to avoid injuring cutaneous nerves. The tendons are retracted to the radial side and the radiocarpal joint space is identified with a 22-gauge needle. Blunt tenotomy scissors or forceps are used to pierce the volar capsule. The portal penetrates the ulnolunate ligament (ULL) adjacent to the radial insertion of the triangular fibrocartilage. A cannula with a blunt trochar is then inserted. Care is taken to situate the portal underneath the ulnar edge of the flexor tendons and to apply retraction solely in a radial direction in order to avoid injury to the ulnar nerve and artery. The ulnar nerve and artery are usually more than 5 mm from

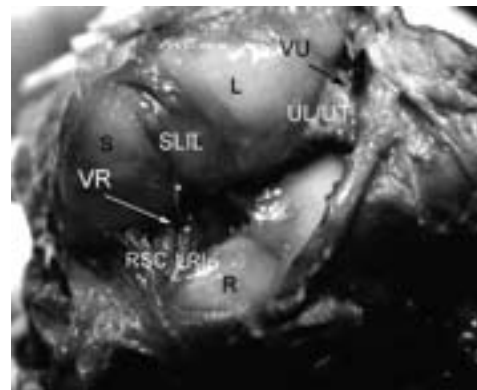


Figure 4.

Ligamentous Interval of VR and VU portals. Radiocarpal joint viewed from the dorsal aspect of a hyperflexed wrist. A needle in the VR portal (*) enters between the radioscapocapitate (RSC) and long radiolunate (LRL) ligaments. A needle in the VU portal enters between the ulnolunate and ulnotriquetral ligaments (UL/UT). S, scaphoid; L, lunate; R, radius; RSL = radioscapolunate ligament, SLIL = scapholunate interosseous ligament. (From Slutsky DJ. The use of a volar ulnar portal in wrist arthroscopy. *The Journal of Arthroscopic and Related Surgery*, 20(2):158–163, 2004; with permission.)

the trochar provided the capsular entry point is deep to the ulnar edge of the profundus tendons. The median nerve is protected by the interposed flexor tendons.

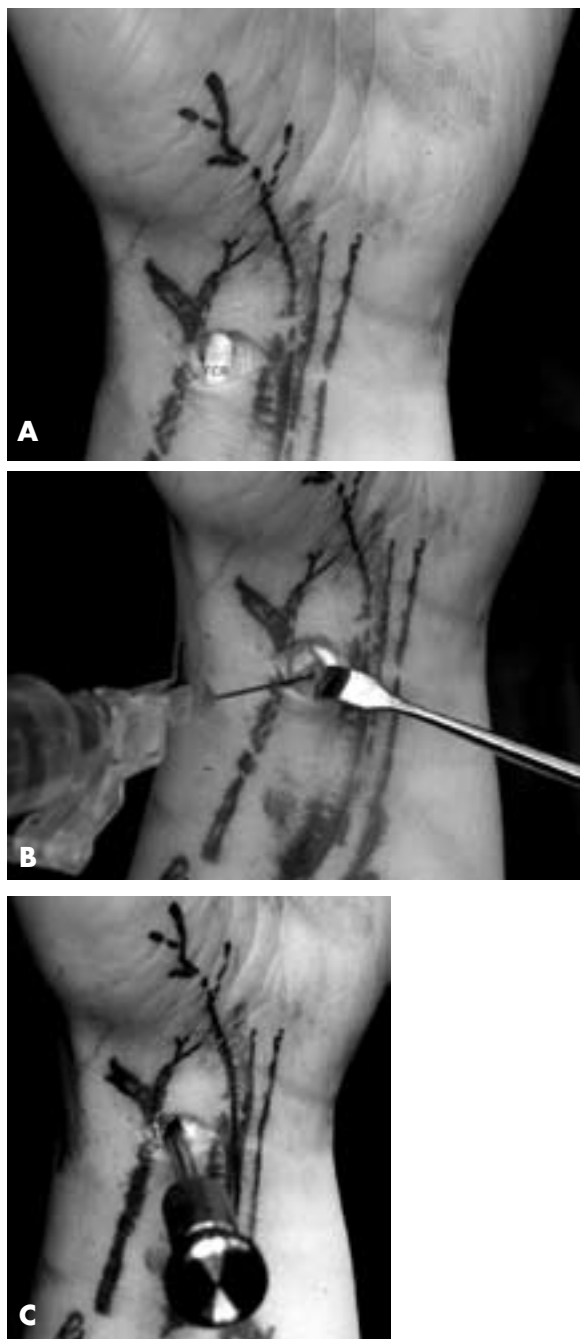


Figure 5.

Technique for VR portal. **A)** Skin incision for VR portal. FCR, flexor carpi radialis tendon. **B)** Saline injection of radiocarpal joint. **C)** Insertion of cannula through floor of the FCR sheath. (From Slutsky DJ. Volar portals in wrist arthroscopy. *JASSH* 2(4):225–232, 2002; with permission.)

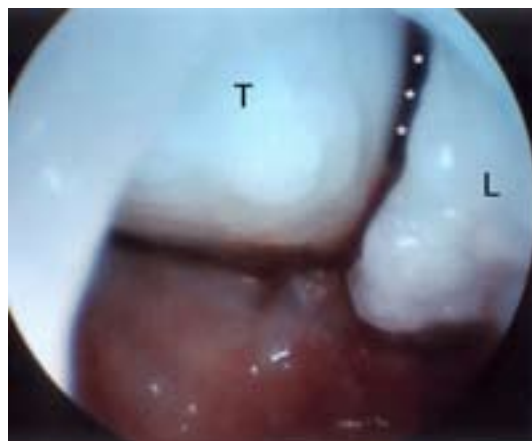


Figure 6.

Lunotriquetral ligament tear as viewed from the VU portal. Note the tear of the lunotriquetral ligament (*). T = triquetrum, L = lunate.

Dorsal Midcarpal Portals

The midcarpal radial (MCR) portal is located 1 cm distal to the 3-4 portal and is bounded radially by the ECRB and ulnarly by the EDC. Flexing the wrist and firm thumb pressure helps identify the soft spot between the distal pole of the scaphoid and the proximal capitate.

The midcarpal ulnar (MCU) portal is found 1 cm distal to the 4-5 portal, and 1.5 cm ulnar and slightly proximal to the MCR portal, in line with the ring metacarpal axis.

Volar midcarpal portals

The volar radial midcarpal (VRM) portal may occasionally be used as an accessory portal for visualizing the palmar aspects of the capitate and hamate in cases of avascular necrosis or osteochondral fractures (Figure 9). This portal facilitates visualization of the volar aspect of the capitolunate interosseous ligament (CHIL), which is important in minimizing translational motion and has an essential role in providing stability to the transverse carpal arch.

The midcarpal joint is identified with a 22-gauge needle through the same skin incision as used for the VR portal, by angling it approximately 1 cm distally and 5° ulnarly. A blunt trochar is then inserted. The trochar passes deep to the superficial palmar branch of the radial artery, which courses more superficially over the scaphoid tuberosity at that level. The distance between the volar radiocarpal and volar midcarpal entry sites averages 11 mm (7–12 mm).

Wrist Arthroscopy: Portals and Procedures

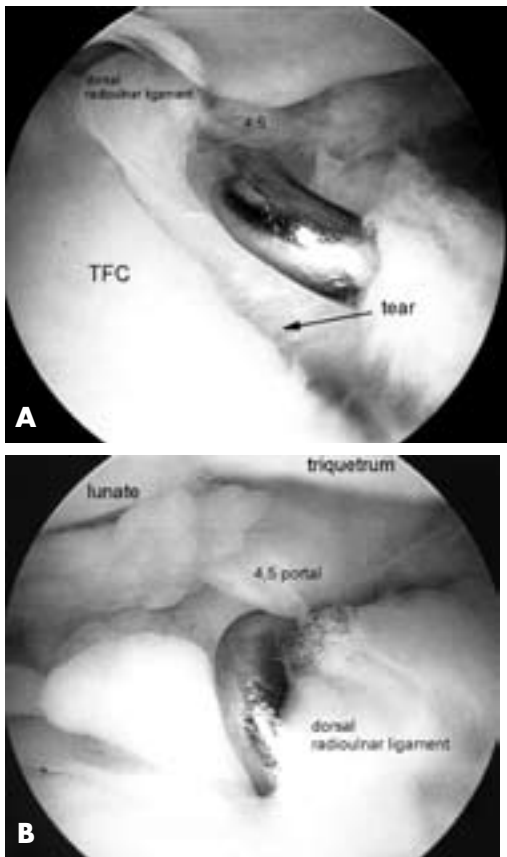


Figure 7.

VU Portal view. **A)** Triangular fibrocartilage (TFC) tear extending into the dorsal radioulnar ligament. Probe inserted through the dorsal 4-5 portal. **B)** Palpation of the dorsal radioulnar ligament tear with the hook probe. (From Slutsky DJ. The use of a volar ulnar portal in wrist arthroscopy. *The Journal of Arthroscopic and Related Surgery* 20(2):158–163, 2004; with permission.)

The triquetro-hamate (TH) portal is an accessory mid-carpal portal that enters the triquetro-hamate joint ulnar to the ECU tendon. This entry site is both ulnar and distal to the MCU. A shallow incision with blunt spreading should be used to avoid injury to branches of the DCBUN (Figure 10).

Dorsal Distal Radioulnar Joint (DRUJ) portals

Both a proximal and a distal dorsal DRUJ portal have been described. DRUJ portals may be used to assess the status of the articular cartilage of the DRUJ, as well as the deep surface and foveal attachment of the TFC. One may also identify loose bodies and synovial hypertrophy. Both portals lie between the ECU and the EDM tendons (Figure 11A–B).

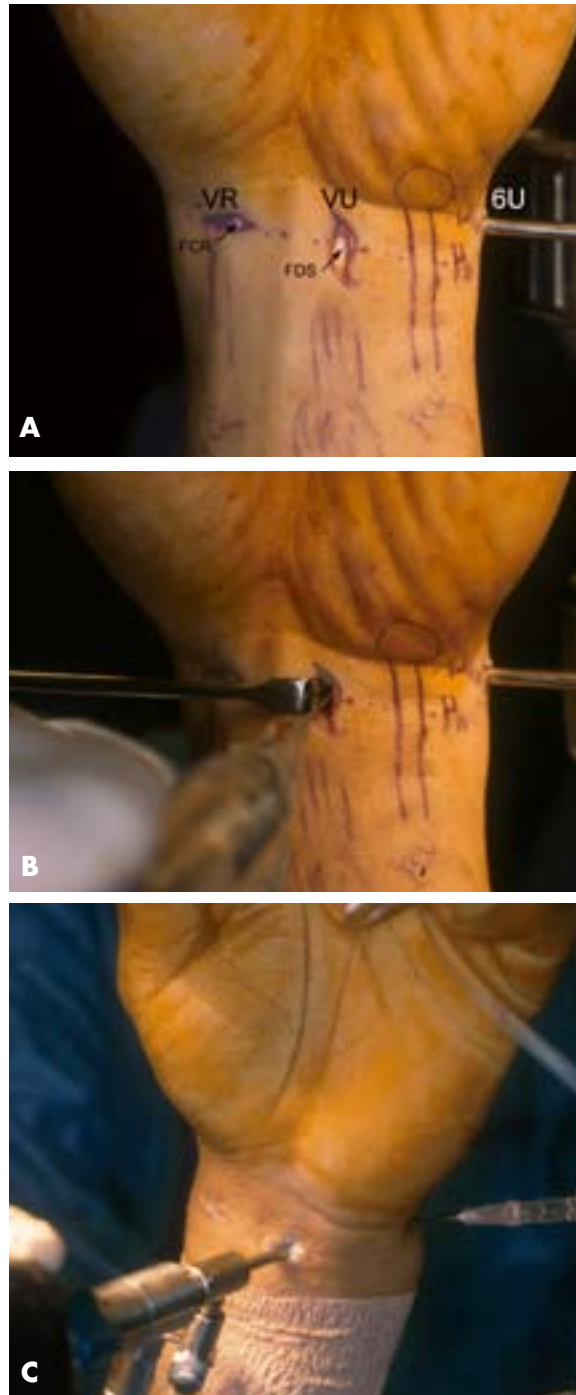


Figure 8.

Technique for VU portal. **A)** Skin incision for VU portal. FCR, flexor carpi radialis tendon; FDS, flexor digitorum sublimus. **B)** FDS retracted, saline injection of radiocarpal joint. **C)** Insertion of cannula through capsule deep to FDS tendons. (From Slutsky DJ. The use of a volar ulnar portal in wrist arthroscopy. *The Journal of Arthroscopic and Related Surgery* Volume 20, Issue 2, Feb 2004, pp. 158–163; with permission.)

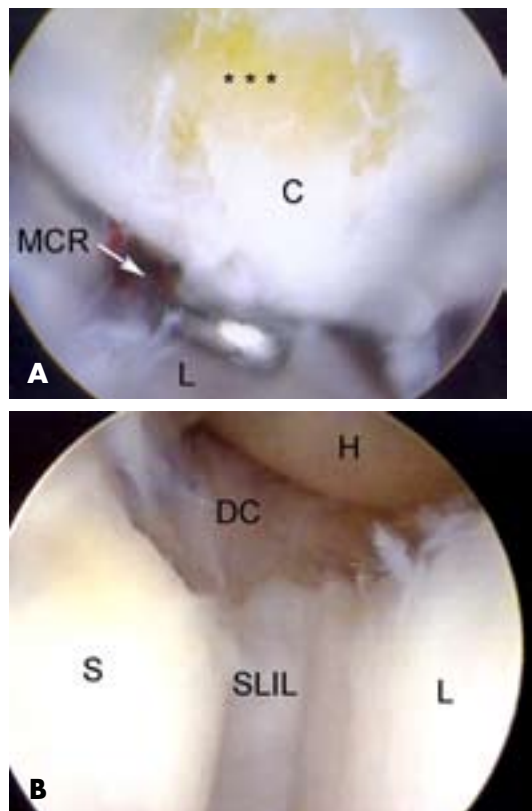


Figure 9.

Volar midcarpal portal. **A)** Chondromalacia of the palmar capitate [C]. Probe is in the midcarpal radial portal (MCR). L = lunate. **B)** Tear of the palmar region of the SLIL (scapholunate interosseous ligament), as viewed from the volar radial midcarpal portal. Note the intact dorsal fibers of the SLIL. S = scaphoid, L = lunate, H = hamate, DC = dorsal capsule.

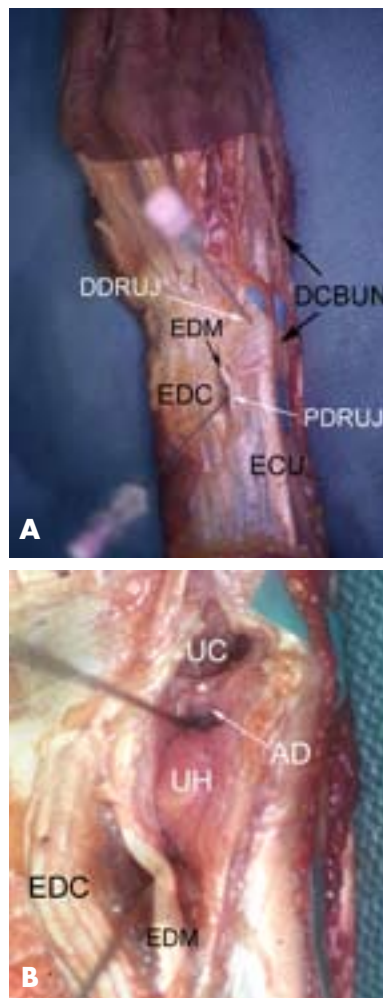


Figure 11.

Dorsal DRUJ portal anatomy. **A)** Relative position of the proximal (PDRUJ) and distal (DRUJ) portals. **B)** Close up with the dorsal capsule removed demonstrating the position of the needles in relation to the dorsal radioulnar ligament (*). AD= articular disk, UC = ulnocarpal joint, UH = ulnar head. From Slutsky DJ. Wrist Arthroscopy Portals. In *Techniques in Hand and Wrist Arthroscopy*. Slutsky DJ, Nagle DJ, eds. Philadelphia: Elsevier, Inc. In press.

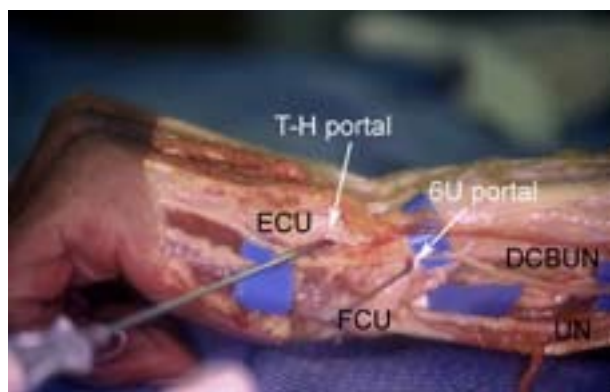


Figure 10.

View of the ulnar aspect of a left wrist demonstrating the relative positions of the triquetrohamate (T-H) portal and the 6U portal. DCBUN = dorsal cutaneous branch of the ulnar nerve, UN = ulnar nerve. From Slutsky DJ. Wrist Arthroscopy Portals. In *Techniques in Hand and Wrist Arthroscopy*. Slutsky DJ, Nagle DJ, eds. Philadelphia: Elsevier, Inc. In press.

The TFCC has the least tension in neutral rotation of the forearm which therefore the optimal position for visualizing the articular dome of the ulnar head and the undersurface of the TFCC from its attachment to the sigmoid notch to its insertion into the fovea of the ulna. Because of the dorsal entry of the arthroscope, the course of the dorsal radioulnar ligament is not visible until its attachment into the fovea. The dorsal radioulnar ligament tends to stretch over the ulnar head as it moves towards the ulnar styloid, making

Wrist Arthroscopy: Portals and Procedures

visualization of the foveal attachment of the TFCC difficult using the dorsal portals.

The relatively dorsal position of the ulnar styloid makes it difficult to insert anything larger than a 1.9 mm scope through these portals, which limits their effectiveness for viewing, but not for instrumentation.

The proximal portal (PDRUJ) is located just proximal to the sigmoid notch and the flare of the ulnar metaphysis. This portal is easier to penetrate, with less risk of chondral injury, than the distal DRUJ portal. The forearm is held in supination to relax the dorsal capsule, to move the ulnar head volarly and to lift the central disc distally from the head of the ulna. Reducing the traction to 1–2 pounds creates more room between the ulna and the sigmoid notch by reducing the compressive force caused by axial traction. The joint space is identified by inserting a 22-gauge needle horizontally at the neck of the distal ulna. Fluoroscopy is used to facilitate needle placement as needed. The joint is insufflated with saline and the capsule is spread with tenotomy scissors through a small incision. A small cannula and trochar for the 1.9 mm arthroscope are introduced.

The distal portal (DDRUJ) is identified with a 22-gauge needle 6–8 mm distally to the PDRUJ portal and just proximal to the 6R portal. This portal can be used for outflow drainage or instrumentation. It lies on top of the ulnar head but underneath the TFCC, making it difficult to use in the presence of a positive ulnar variance.

Volar Distal Radioulnar Joint Portal

The volar distal radioulnar (VDRU) portal is useful for assessing the deep surface and foveal attachment of the TFCC (Figure 12). It may be used in cases where there is suspicion of TFC detachment from the fovea (Figure 13). A 1.9 mm small joint arthroscope may be used, especially in a small wrist, but I have found that a standard 2.7 mm scope provides a better field of view.

The VDRU portal is accessed through the same skin incision used for the VU portal. The joint is first identified by angling a 22-gauge needle 45° proximally, and then injecting the DRUJ with saline. It is useful to leave a needle or cannula in the ulnocarpal joint for reference during this step; the capsular entry point for the VDRU lies 5 mm to 1 cm proximal to the ulnocarpal joint (Figure 14A–B). Alternatively, a probe can be placed in the distal DRUJ portal and advanced through the palmar incision to help locate the joint space. Once the correct plane is identified, the volar DRUJ capsule is pierced with tenotomy

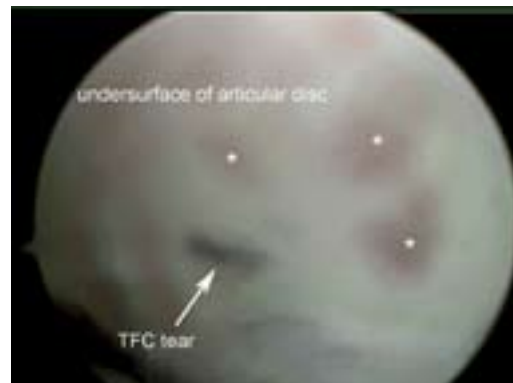

Figure 12.

View from the palmar DRUJ portal. The undersurface of the articular disc demonstrates a tear of the triangular fibrocartilage (TFC) along with synovitis (*).

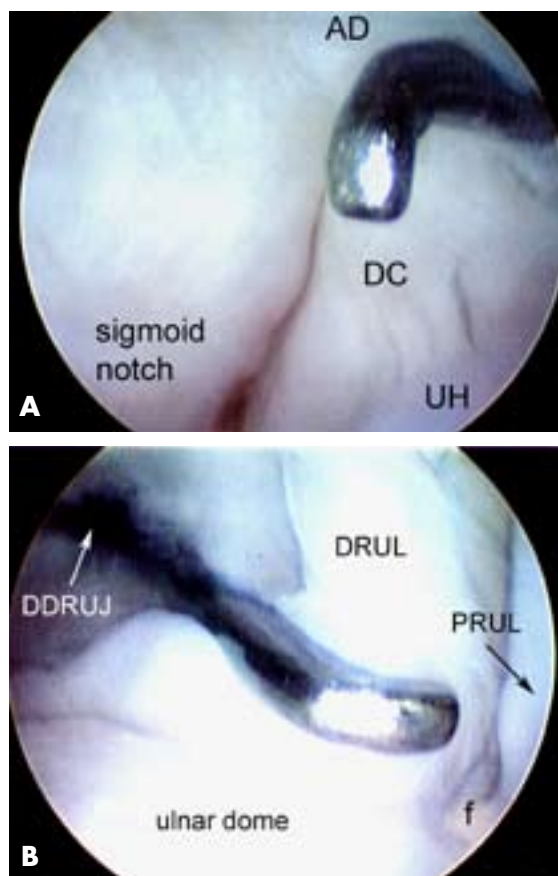


Figure 13.

View from the VDRU portal. **A)** View of the sigmoid notch from the palmar aspect of the wrist. AD = articular disc, DC = dorsal DRUJ capsule, UH = ulnar head. **B)** View of an intact foveal attachment. Probe is in the distal dorsal radioulnar joint portal (DDRUJ). PRUL = palmar radioulnar ligament, DRUL = dorsal radioulnar ligament.

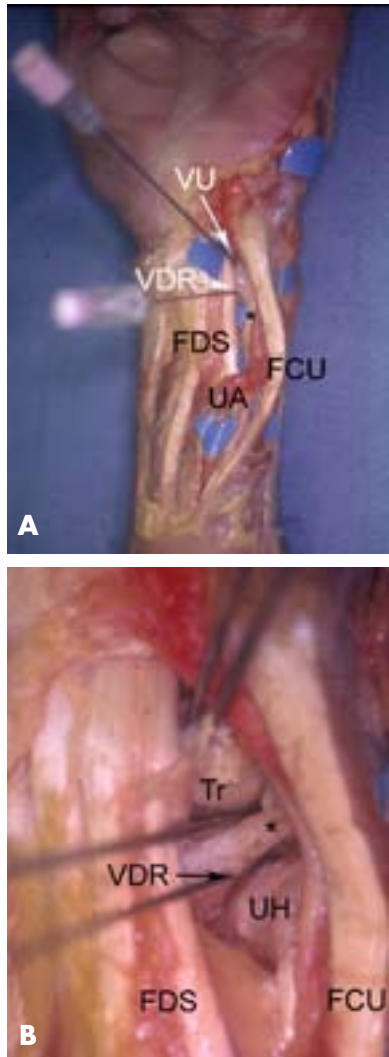


Figure 14.

Volar DRUJ portals. **A)** Volar aspect of a left wrist demonstrating the relative positions of the VU and volar DRUJ (VDR) portals in relation to the ulnar nerve (*) and ulnar artery (UA). FDS = flexor digitorum sublimis, FCU = flexor carpi ulnaris. **B)** Close up view after the volar capsule is removed showing position of needles in relation to the volar radioulnar ligament (*). Tr = triquetrum, UH = ulnar head. From Slutsky DJ. *Wrist Arthroscopy Portals*. In *Techniques in Hand and Wrist Arthroscopy*. Slutsky DJ, Nagle DJ, eds. Philadelphia: Elsevier, Inc. In press.

scissors followed by a cannula with a blunt trochar and then the arthroscope. Initially, the space appears quite limited but over the course of 3–5 minutes the fluid irrigation expands the joint space which improves visibility. Instrumentation is inserted through the dorsal distal DRUJ portal.

Contraindications

Contraindications to wrist arthroscopy would include any cause of marked swelling which distorts the topographic anatomy, large capsular tears which might lead to extravasation of irrigation fluid, neurovascular compromise, bleeding disorders or infection.

II. Procedures

Equipment and Implants

In general, a 2.7 mm 30° angled arthroscope is used, although 1.9 mm or 2.3 mm scopes may be used instead. A 3 mm hook probe is needed for palpation of intracarpal structures. Some method of overhead traction is useful. This may include traction from the overhead lights or a shoulder holder along with 5–10 lb weights attached to an arm sling. A traction tower such as the Linatec tower (Conmed—Linatec Corporation, Largo, FL) or the ARC traction tower designed by Dr. William Geissler (Arc Surgical LLC, Hillsboro, OR) facilitate instrumentation. Motorized shavers and possibly a diathermy unit such as the Oratec probe (Smith and Nephew, NY) are used for debridement.

Ancillary equipment is largely procedure dependent. A motorized 2.9 mm burr is needed for bony resection. There are a variety of commercially available suture repair kits including the TFCC repair kit by Linatec (Conmed—Linatec Corporation, Largo, FL). TFC repairs can also be facilitated by use of a Tuohy needle which is generally found in any anesthesia cart. Specially designed jigs have been made to facilitate repair of radial TFCC tears.

Methodology

Under general anesthesia, the patient's hand is suspended with 10–15 lbs. of counter traction. The arm is exsanguinated and an upper arm tourniquet inflated to 250 mm Hg. The surgeon is seated facing the dorsal surface of the wrist when creating the dorsal portals and is seated facing the volar aspect of the wrist when creating the volar portals. Before creation of the initial portal, the radiocarpal joint space is identified with a 22-gauge needle and the joint inflated with the joint is injected with 5 cc of saline. Inflow through the arthroscope's cannula, with outflow through a cannula or 18-gauge needle in the 6U portal is standard.

It is useful to have a systematic approach to viewing the wrist. The structures that should be visualized as a part of a standard exam include the cartilaginous surfaces of all artic-

Wrist Arthroscopy: Portals and Procedures

ulations, the scapho-lunate, luno-triquetral, radioscapho-capitate (RSC), long radiolunate (LRL), radioscapholunate (RSL), ulnolunate (UL), and ulnotriquetral (UT) ligaments, and the TFC.

It is my practice is to establish the dorsal portals first but then to start the arthroscopic examination with the VR portal in order to visualize the volar SLIL and the DRCL ligament to minimize iatrogenic trauma to the dorsal capsular structures. In patients with ulnar sided wrist pain, the VU portal is used to assess the palmar LTIL and DRUL, ECU subsheath and radial TFCC attachment. The scope is then inserted in the 3-4 portal followed by various combinations of the 4-5 portal and 6R portal. The 6U portal is used mainly for outflow, but it may be used for instrumentation when debriding volar LTIL tears. Midcarpal arthroscopy is then performed to probe the SLIL and LTIL joint spaces for instability, to visualize the capitoamate interosseous ligament (CHIL), and to identify any chondral lesions or loose bodies. The special use portals, such as the dorsal and volar DRUJ portals and the 1-2 portal, are used as needed.

The number of conditions that are amenable to arthroscopic treatment continues to grow. Many arthroscopic procedures are now common place while others still await clinical validation. Some of the more standard procedures are discussed below:

Arthroscopic Wrist Ganglionectomy

Indications

The indication for arthroscopic removal of a dorsal ganglion is similar to the those for an open method. I personally reserve the arthroscopic procedure for patients who have concomitant wrist pain, where evaluation of any associated carpal instability is desirable. Another good indication is in the treatment of an occult ganglion, which is entirely intracapsular and therefore cannot be visualized during open surgery.

Contraindications

Previous scarring in the area due to previous injury or surgery for recurrence may distort the anatomy and make it difficult to establish the portals.

Surgical technique—Dorsal ganglionectomy

An arthroscopic survey is performed starting with the dorsal ulnar portals. Since the ganglion overlies the 3-4 portal, it is my preference to view the ganglion through the volar radial portal, which provides a direct line of sight. Alternatively,

the 1-2 or 6-R portal can be used to obtain a tangential view of the ganglion and the scapholunate interosseous ligament. A shaver is then introduced into the ganglion through the 3-4 portal to perforate the ganglion and resect the stalk. Care must be taken not to injure the dorsal aspect of the SLIL. The intra articular ganglion is completely debrided along with a 1 cm area of surrounding dorsal capsule. The extensor tendons are usually visible through the defect. If the external ganglion mass is still tense, the 3-4 portal can be widened to allow the cyst to drain into the joint.

The 3-4 portal can then be used to complete the arthroscopic survey after resection. Midcarpal arthroscopy should be performed in every case to assess the status of the SLIL. If the ganglion extends into the midcarpal joint it is debrided with a shaver introduced through the radial midcarpal portal. Dynamic SLIL instability is treated separately as necessary.

Surgical technique—Volar ganglionectomy

Although I prefer to insufflate the joint prior to portal creation, some authors prefer to examine the joint initially without fluid in order to define the ganglion stalk. The joint is surveyed in the standard fashion starting with the 3-4 portal. When a volar ganglion is present, there may be significant redundancy of the capsule or an out-pouching in the sulcus between the RSC and LRL. This out-pouching and capsular redundancy can be exaggerated and visualization facilitated by placing pressure on the wrist capsule from the volar side. A motorized shaver is used to debride the lesion and resect the volar capsule between the two extrinsic ligaments. The VR portal can be used to facilitate this step.

Rehabilitation

Postoperatively, the patients are splinted for comfort for a brief period of 4–7 days. Active wrist motion is encouraged after this period of time and patients are allowed activities of daily living followed by gradual strengthening.

Arthroscopic Release of Wrist Contracture

Indications

Wrist contractures can occur following any type of wrist injury, but are most prevalent following distal radius fractures. Patients lacking a functional arc of wrist motion (5° flexion, 30° extension, 15° radial deviation, 10° ulnar deviation) who have failed a trial of dynamic/static progressive splinting are candidates for this procedure. Volar capsulotomies are less risky and are indicated to regain wrist

extension. Dorsal capsulotomies are necessary to regain wrist flexion but they may require use of a volar arthroscopy portal and are technically more difficult.

Contraindications

Frank carpal instability is a contraindication since release of the volar and/or dorsal extrinsic ligaments would likely exacerbate this condition. Division of the radioscaphocapitate (RSC), long radiolunate (LRL) and short radiolunate (SRL) ligaments should be performed with caution in patients who are at risk for ulnar translocation, such as patients with rheumatoid arthritis and those who have undergone previous radial styloidectomies. Patients who cannot comply with postoperative dynamic/static progressive splinting due to low pain threshold or psychological disorder are not appropriate candidates.

Surgical technique

Volar Capsulotomy: The 3-4 and 4-5 portals are established. A blunt trocar with cannula is inserted through the 3-4 portal and used in a sweeping fashion to clear a path for the arthroscope and the instrumentation in cases of severe arthrofibrosis. Clearing the intra-articular adhesions is tedious but essential in order to adequately visualize the capsular ligaments. Midcarpal arthroscopy should be performed to assess the scapholunate and lunotriquetral joints. Evidence of dynamic instability will affect the decision making with regards to which volar and dorsal ligaments may be released. A suction punch and full radius resector are used to clear adhesions off the volar capsule until the RSC, LRL, radioscapholunate ligament (RSL) and SRL respectively are well defined. Anatomic and MRI studies by Verhellen and Bain determined that the average distance between the volar joint capsule and the radial artery is 5.2 mm, the median nerve 6.9 mm and the ulnar nerve 6.7 mm. While viewing through the 3-4 portal, an arthroscopic knife is introduced through a cannula placed in the 4-5 portal (Figure 15). The cannula is necessary in order to protect the extensor tendons from inadvertent laceration during insertion and removal of the knife. The tip of the blade should be visualized at all times to prevent inadvertent perforation of the capsule, or chondral damage. The RSC ligament is gently sectioned until the volar capsular fat and/or the flexor carpi radialis tendon is seen.

In order to section the ulnolunate (ULL) and ulnolunotriquetral (ULT) ligaments, it is often necessary to establish a 6R portal since instrumentation and viewing

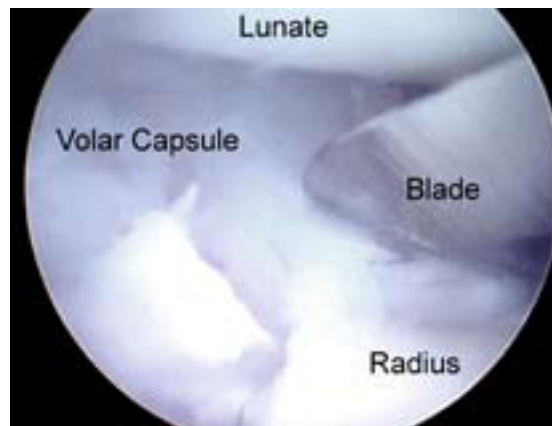


Figure 15.

Arthroscopic wrist capsulotomy. View of a volar capsulotomy from the 3-4 portal. From Slutsky DJ. Wrist Capsulotomy. In *Techniques in Hand and Wrist Arthroscopy*. Slutsky DJ, Nagle DJ, eds. Philadelphia: Elsevier, Inc. In press.

across the radiocarpal joint is often limited due to scar. The 6U portal may be used interchangeably for instrumentation. The ULL and ULT ligaments should not be released in the presence of a lunotriquetral ligament tear since the combination of these results in a volar intercalated segmental instability pattern in sectioning studies, especially when the dorsal radiocarpal ligament is also released.

Dorsal Capsulotomy: It is my preference to use a volar radial (VR) portal as previously described, although the 1-2 portal may be substituted or added. If both volar and dorsal capsulotomies are performed it is preferable to release the dorsal capsule first, since prior release of the volar capsule will make establishment of the VR portal more difficult. A hook probe is inserted in the 3-4 portal. A suction punch and full radius resector are exchanged with the probe or inserted through the 1-2 portal to clear adhesions until the dorsal capsule and the DRCL are seen. In patients with a partial or complete scapholunate ligament tear, sectioning the DRCL should be done with caution since it may exacerbate any pre-existing scapholunate instability.

While visualizing through the VR portal, an arthroscopic knife is then introduced through a cannula placed in the 3-4 portal (Figure 16). The dorsal capsule and the DRCL are gently sectioned until the dorsal capsular fat and/or the extensor tendons can be seen. Bain uses umbilical tape to retract and protect the extensor tendons. The wrist should

Wrist Arthroscopy: Portals and Procedures

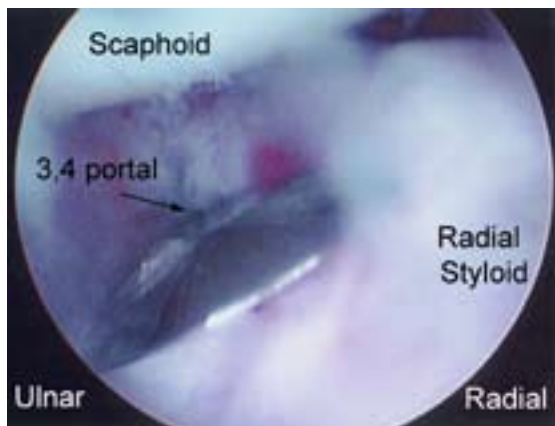


Figure 16.

Arthroscopic wrist capsulotomy. View of a dorsal capsulotomy from the VR portal. From Slutsky DJ. Wrist Capsulotomy. In *Techniques in Hand and Wrist Arthroscopy*. Slutsky DJ, Nagle DJ, eds. Philadelphia: Elsevier, Inc. In press.

be taken out of traction and the amount of extension assessed. If the surgeon desires to release the dorsoulnar capsule, it is necessary to establish a volar ulnar (VU) portal, or to view through the 6U portal. The adhesions are cleared through use of the 4-5 and 6R portals and the capsulotomy performed in a similar fashion.

Postoperative management

Bleeding may be quite brisk hence postoperative hematomas are minimized by the use of a compressive dressing. Excessive bleeding requires insertion of a hemovac drain for the first 24–48 hours. Immediate finger motion is instituted. Protected wrist motion is started within the first week, followed by dynamic and/or static progressive wrist flexion and/or extension splinting as soon as patient comfort allows.

Radial Styloidectomy

Indications

The indications for an arthroscopic radial styloidectomy are similar to the open procedure. Radial styloid impingement due to a longstanding scaphoid nonunion or scapholunate dissociation is a common indication.

Contraindications

The main risk following a radial styloidectomy is ulnar translocation of the carpus. If > 6 mm of the styloid is removed the capitate is destabilized so that it no longer

rests in the lunate fossa, resulting in radial instability. Therefore, bony resection is restricted to no more than 4 mm. Patients who do not have an intact RSC ligament due to distal radius fracture (Figure 17) or radiocarpal dislocation are at risk for ulnar translocation and are not candidates for this procedure, especially if a proximal row carpectomy is contemplated. Ulnar translocation is a frequent sequella of longstanding rheumatoid disease hence any patient with chronic wrist involvement is a poor candidate for this procedure.

Surgical technique

The 1-2 and 3-4 portals are established. A large bore outflow cannula is placed through the 4-5 or 6U portal. I use the volar radial (VR) portal interchangeably with the 3-4 portal for viewing and instrumentation in order to gain complete access to the dorsoradial aspect of the styloid. With the arthroscope in the 3-4 portal, the origins of the RSC and LRL on the distal radius are noted, which mark the ulnar limit of the resection. The diameter of the burr will give a rough guide as to the amount of bony resection, but this needs to be confirmed fluoroscopically. Enough bone should be resected so that there is no residual impingement between the scaphoid and the radial styloid when the wrist is radially deviated with the traction released (Figure 18A–F). A small osteotome may be used judiciously since inadvertent penetration of the radial joint capsule carries the risk of radial artery perforation as it traverses the snuff box.

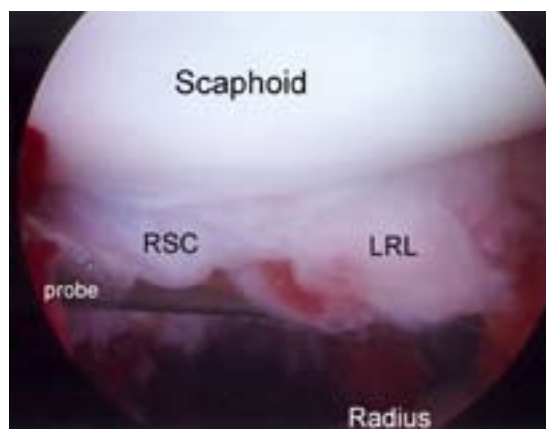


Figure 17.

Avulsion of the radioscaphocapitate (RSC) and long radiolunate ligament (LRL). From Slutsky DJ. Radial Styloidectomy. In *Techniques in Hand and Wrist Arthroscopy*. Slutsky DJ, Nagle DJ, eds. Philadelphia: Elsevier, Inc. In press.

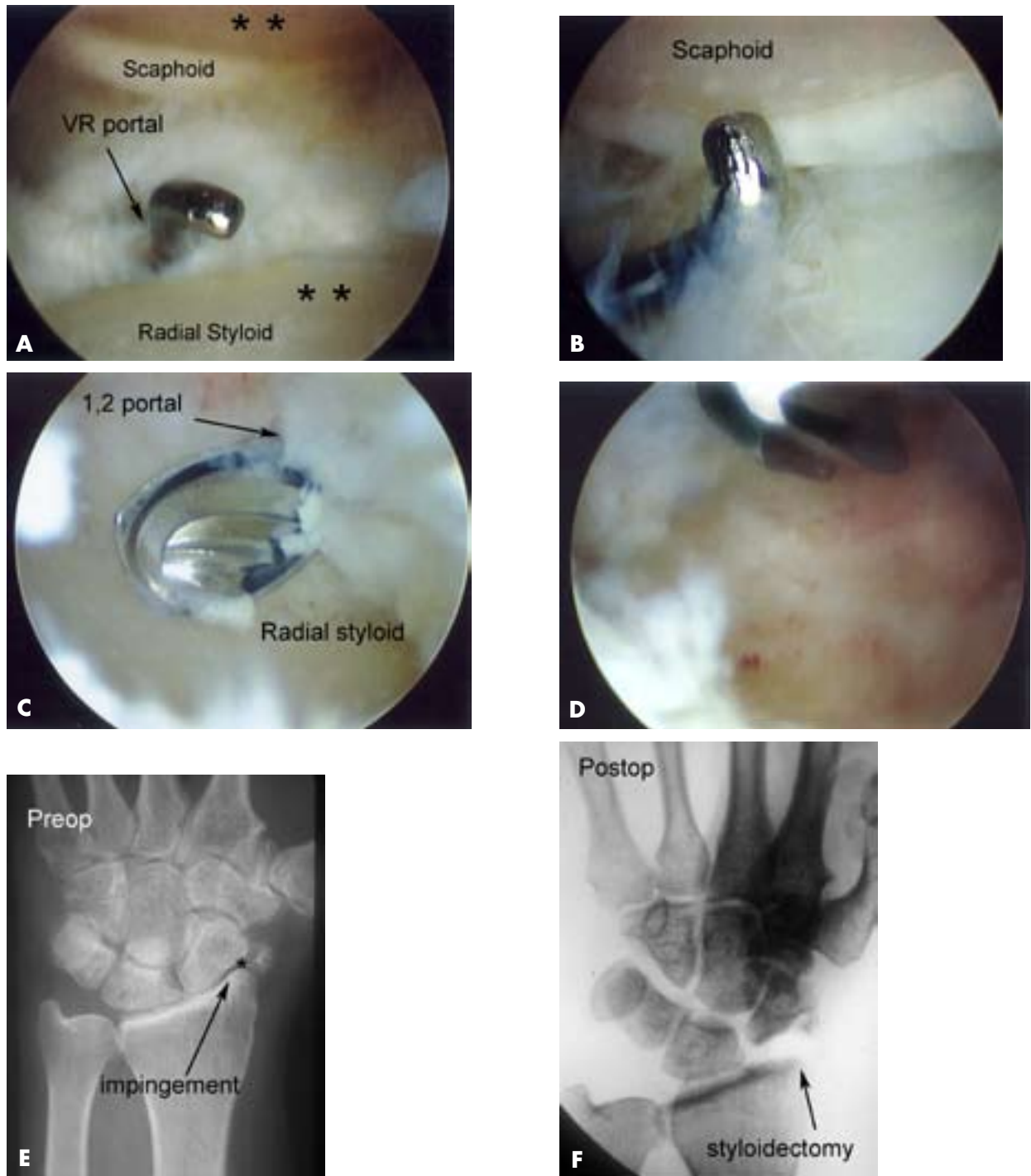


Figure 18.

Arthroscopic radial styloidectomy. **A)** View from the 1-2 portal with the probe in the VR portal. Note the chondromalacia (*) on the radial styloid and adjacent scaphoid. **B)** Close up of the scaphoid pole. **C)** View from the VR portal with an arthroscopic burr in the 1-2 portal. **D)** After completion of the radial styloidectomy. **E)** Preoperative x-ray showing radial styloid narrowing due to a chronic scapholunate dissociation. **F)** Postoperative x-ray showing the amount of bony resection. From Slutsky DJ. Radial Styloidectomy. In *Techniques in Hand and Wrist Arthroscopy*. Slutsky DJ, Nagle DJ, eds. Philadelphia: Elsevier, Inc. In press.

Wrist Arthroscopy: Portals and Procedures

Rehabilitation

The patient is placed in a removable below elbow splint for comfort and protected wrist motion is instituted after the first week. Gradual strengthening exercises are added as tolerated by the 3rd–4th week.

Proximal Pole of Hamate Resection

Cadaver studies have revealed that cartilage erosion of the proximal pole of the hamate is the most common site of arthrosis within the wrist (Figure 19). It is noted almost exclusively in specimens with type II lunates that have a separate facet that articulates with the proximal pole of the hamate, and it is presumed to be a result of the long term overloading of the proximal hamate. Harley et al noted an association between this arthrosis and lunotriquetral interosseous ligament tears. They noted favorable results in the majority of patients treated by arthroscopic excision of the proximal hamate. That study also demonstrated that resection of 2.4 mm of the proximal pole of the hamate unloaded the hamato-lunate articulation without altering the load across the triquetro-hamate articulation.

Indications

Patients with persistent ulnar sided wrist pain due to arthrosis of the proximal pole of the hamate and who have failed an adequate trial of nonoperative management are appropriate candidates for this procedure. The history and physical findings are usually not diagnostic, although occasionally cystic change of the proximal hamate pole is noted on x-ray or marrow edema of that area is seen on MRI. Most often, the condition is diagnosed at the time of arthroscopy and is found in association with other ulnar sided wrist pathology.

Contraindications

Inflammatory arthritis or autoimmune disease that involves the wrist is a contraindication. Resection of the proximal hamate in a patient with minimal or focal chondromalacia is controversial. Patients with diffuse degenerative change and/or interosseous ligament tears will have compromised outcomes and may be more suitable for partial fusions or proximal row carpectomy.

Surgical technique

The proximal pole of the hamate is most clearly evaluated with the arthroscope in the MCU portal. Instability of the LT interval is best assessed with the arthroscope in the MCR

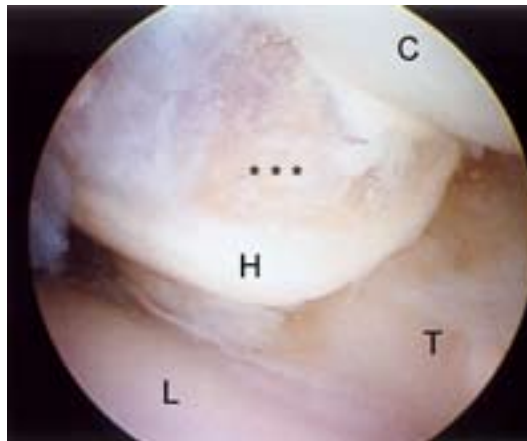


Figure 19.

Chondromalacia (*) on the proximal pole of the hamate (H). C = capitate, L = lunate, T = triquetrum.

portal and a probe in the MCU portal. A synovectomy performed as needed to enhance visualization of the cartilage, which should also be probed to define the extent of any chondromalacia that is present.

With the arthroscope in the MCR portal, the MCU portal is used for instrumentation (2.7 mm full radius resector and a 2.9 mm burr). After the subchondral bone of the proximal hamate has been exposed with the shaver, 2–4 mm proximal pole of the hamate can be excised using the burr. Care must be taken to avoid damage to the cartilage surfaces of the proximal capitate or the adjacent triquetrum. The most volar and distal portion of the proximal hamate resection is poorly visualized from the MCR portal. It is necessary to switch the arthroscope to the MCU portal in order to clearly visualize the full extent of the volar resection of the proximal hamate. Infrequently, the shaver or burr is placed into the MCR portal to complete the proximal hamate resection. The 2.9 mm burr can be used as a gauge to assess the adequacy of the bony resection. When placed in the area of resection, the exposed burr edge should lie nearly adjacent to the proximal capitate surface. Intraoperative fluoroscopy is used to confirm the adequacy of the proximal hamate resection. Any associated LTIL or TFCC tear is treated concomitantly as described below.

Rehabilitation

This is largely dictated by the treatment of any associated pathology. Following a proximal pole debridement with or without LTIL debridement, early active wrist motion is instituted.

Arthroscopic Dorsal Radiocarpal Ligament Repair

Tears of the DRCL have been linked to the development of both volar and dorsal intercalated segmental instabilities and may be implicated in the development of midcarpal instability. In most series, the DRCL is overlooked during the arthroscopic examination of the wrist (Figure 20). The existence of a DRCL tear when combined with a scapholunate interosseous ligament (SLIL) tear connotes a greater degree of carpal instability. This is highlighted in the classification scheme in Table 2.

Indications

An arthroscopic repair is indicated for stage I, or isolated DRCL tears due to the favorable outcomes that can be achieved. Repairs may also be considered in stage II and IIIA DRCL tears, where the associated interosseous ligament tear or TFCC tear is debrided or repaired, with or without pinning. Stage IIIB and stage IV tears will likely be unresponsive to repair since the outcomes appear to be strongly influenced by the results of treatment of the coexisting wrist pathology, which can lead to a mixed clinical picture.

Contraindications

When the treatment of an SLIL tear or dynamic scapholunate instability includes some type of dorsal capsulodesis, the dorsal incision followed by the creation of a dorsal capsular checkrein to restrain palmar flexion of the scaphoid renders any separate treatment of the DRCL tear unfeasible. When the DRCL tear is seen in association with palmar midcarpal instability (MCI), a soft tissue repair of the dorsal ligaments either open or arthroscopic, will not by itself correct the MCI.

Surgical technique

The surgeon sits facing the palm while viewing the DRCL through the VR portal, while the instrumentation is introduced through the dorsal portals. A useful landmark when viewing from the VR portal is the intersulcal ridge between the scaphoid and lunate fossae. The radial origin of the DRCL is seen immediately ulnar to this, just proximal to the lunate. A hook probe is inserted through the 3-4 portal and used to assess the volar aspect of the SLIL and the DRCL.

An outside-in repair technique is currently recommended. A curved 18 or 21 gauge spinal needle is inserted through the 4-5 portal and a 2-0 absorbable suture is passed through it. The end of the suture is retrieved with a suture lasso or grasper inserted through the 3-4 portal. A curved

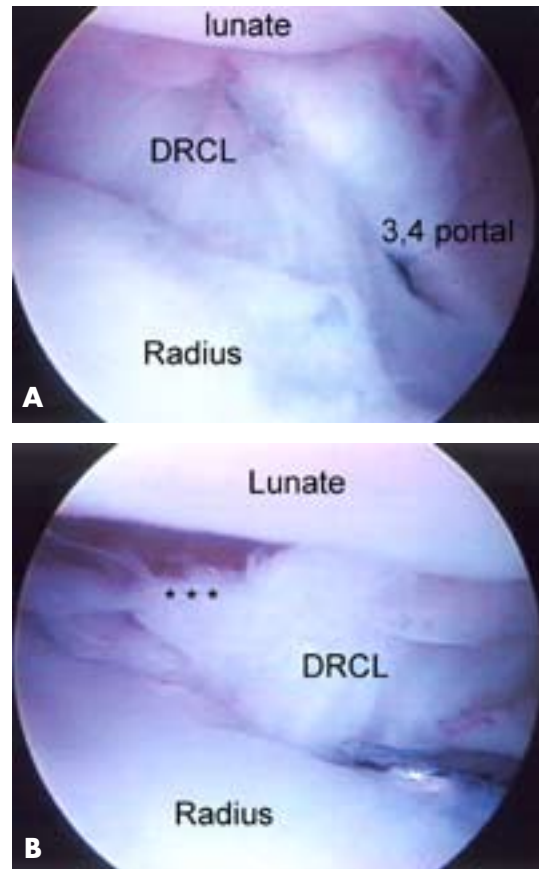


Figure 20.

VR portal view. **A)** Normal dorsal radiocarpal ligament. Hook probe is inserted through the 3/-4 portal. SLIL, scapholunate interosseous ligament; DRCL, dorsal radiocarpal ligament. **B)** DRCL tear (*). Hook probe inserted through the 3-4 portal.

hemostat is used to pull either end of the suture underneath the extensor tendons, and the knot is tied either at the 3-4 or 4-5 portal. The repair is augmented with thermal shrinkage if the torn edge of the DRCL is voluminous and still protrudes into the joint after the sutures are tied (Figure 21A-H).

Rehabilitation

Following the repair the patient is placed in a short arm splint with the wrist in neutral rotation. Early finger motion and edema control are instituted. At the first postoperative visit the sutures are removed and the patient is placed in a short arm cast for a total immobilization time of 6 weeks. Wrist motion with use of a removable splint for comfort is instituted following cast removal. Gradual strengthening

Table 2. Classification of Dorsal Radiocarpal Ligament Tears

Stage I	Isolated DRCL tear
Stage II	DRCL tear with associated dynamic SL ± LT instability ± midcarpal instability
Stage IIIA	SLIL tear, or LTIL tear, or TFCC tear
Stage IIIB	Two or more of the above
Stage IV	Chondromalacia with widespread carpal pathology

Each successive stage denotes a longer standing and/or more severe condition which negatively impacts the prognosis.

SL = scapholunate
 LT = lunotriquetral
 SLIL = scapholunate interosseous ligament
 LTIL = lunotriquetral interosseous ligament
 TFCC = triangular fibrocartilage complex

Adapted from Slutsky DJ. Arthroscopic Dorsal Radiocarpal Ligament Repair. In *Techniques in Hand and Wrist Arthroscopy*. Slutsky DJ, Nagle DJ, eds. Philadelphia: Elsevier, Inc. In press.

exercises are added after 8 weeks. Dynamic wrist splinting is instituted at 10 weeks, as needed.

Scapholunate Ligament Injuries

Arthroscopy has perhaps influenced the diagnosis and treatment of scapholunate ligament injuries more than any other type of carpal disorder. Scapholunate ligament instability has been graded by Geissler (Table 3). Predynamic instability is defined as a Geissler I or II injury in which a probe can be inserted into the scapholunate interval during midcarpal arthroscopy yet the SLIL is palpably intact (Figure 22). Arthrograms and X-rays will be normal in this case. Unstable wrists with a demonstrable scapholunate gap on grip films or motion studies without a DISI deformity are now classified as dynamic instabilities. Unstable wrists with a static DISI pattern typically have associated tears of the DIC and DRCL.

Indications

Arthroscopic assessment of the SLIL is indicated in any patient with radial sided wrist pain who has not responded to nonoperative measures. It is also indicated when there is

a SL gap without a DISI deformity. Arthroscopy allows for staging of the degree of injury and the severity of instability, which guides subsequent treatment. In the presence of long-standing instability with secondary arthritis, arthroscopy allows for assessment of the degree of articular degeneration which guides further treatment options such as limited wrist fusions or proximal row carpectomy.

Contraindications

Complete and repairable SLIL tears as well as static carpal instabilities are best managed with open techniques. Rosenwasser et al. has treated complete but irreparable ligament tears with the RASL procedure (Reduction and Association of the Scaphoid and Lunate) which uses a cannulated Herbert screw to create a stable pseudarthrosis. Hausman has reported favorable results with an arthroscopic version of the RASL.

Surgical technique

The 3-4, 4-5, 6U, 6R, MCR and MCU portals are used to thoroughly assess and treat any scapholunate disorders. The VR portal is useful for assessing tears that are restricted to the volar SLIL as well as any associated DRCL tears (see DRCL repair). The scapholunate joint should be viewed with the scope in the MCU, whereas the lunotriquetral joint should be viewed with the scope in the MCR. Normally there is very little step-off between the distal articular surfaces of the scaphoid and lunate.

Arthroscopic debridement: Arthroscopic debridement is indicated for either acute or chronic tears limited to the volar and/or membranous portion of the SLIL with only Geissler Grade 1 or 2 instability. In these cases, symptoms are likely due to mechanical impingement from the torn ligament edges during wrist motion. The tear is debrided by switching the arthroscope and resector between the 3-4 and 4-5 radiocarpal portals. The torn portion of the SLIL is debrided to stable margins while ensuring that any intact fibers are preserved. Any associated DRCL tears are repaired arthroscopically. Tears with grade 3-4 instability require additional treatment.

Thermal shrinkage: Although some investigators have reported promising short-term results in small numbers of patients with dynamic instability, large long-term prospective studies are still lacking and this technique should therefore be approached with caution. The indications for thermal collagen shrinkage are the same as for debridement. In addition, thermal shrinkage may have some use in the treatment of associated dynamic instability. The dorsal SLIL

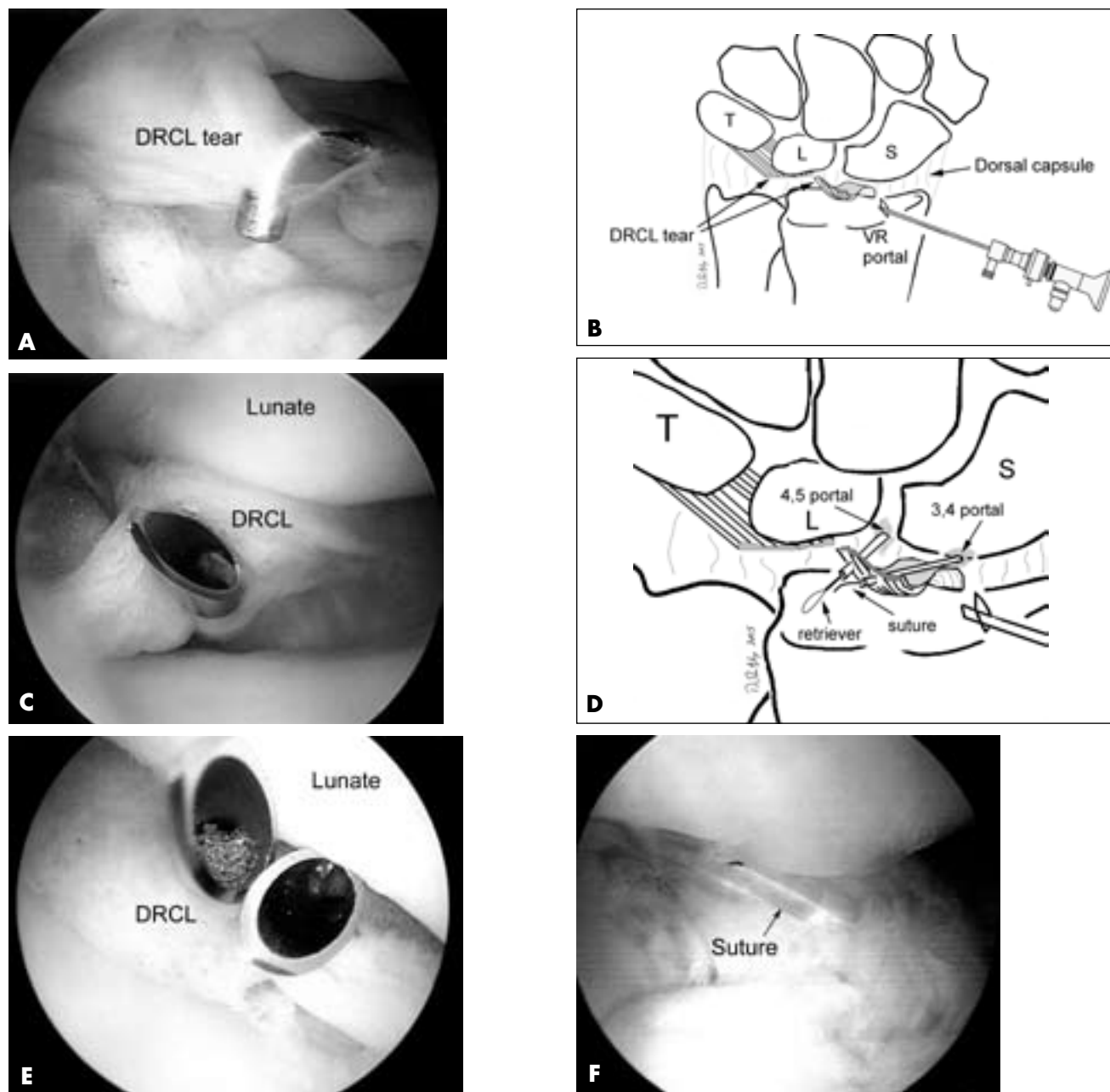


Figure 21. (continued on next page)

Arthroscopic outside-in dorsal radiocarpal ligament (DRCL) repair. **A)** Arthroscopic view of a DRCL tear from the VR portal. **B)** Drawing of DRCL tear. **C)** Insertion of curved spinal needle through edge of DRCL tear. **D)** Drawing of outside-in technique. **E)** Insertion of 2nd spinal needle. **F)** Arthroscopic view of suture loop prior to tying. *Arthroscopy: The Journal of Arthroscopic and Related Surgery* 2005 Dec, 21 (12):1486e–1486e8; with permission.

is shrunk using a thermal probe in the 4-5 portal. The volar SLIL can be shrunk with the probe in the 3-4 portal while viewing through the VR portal. It is important to use rapid

irrigation to limit possible thermal damage to the cartilage. The temperature of the outflow fluid can be monitored to help gauge this. Large bore outflow cannulas are desirable

Wrist Arthroscopy: Portals and Procedures

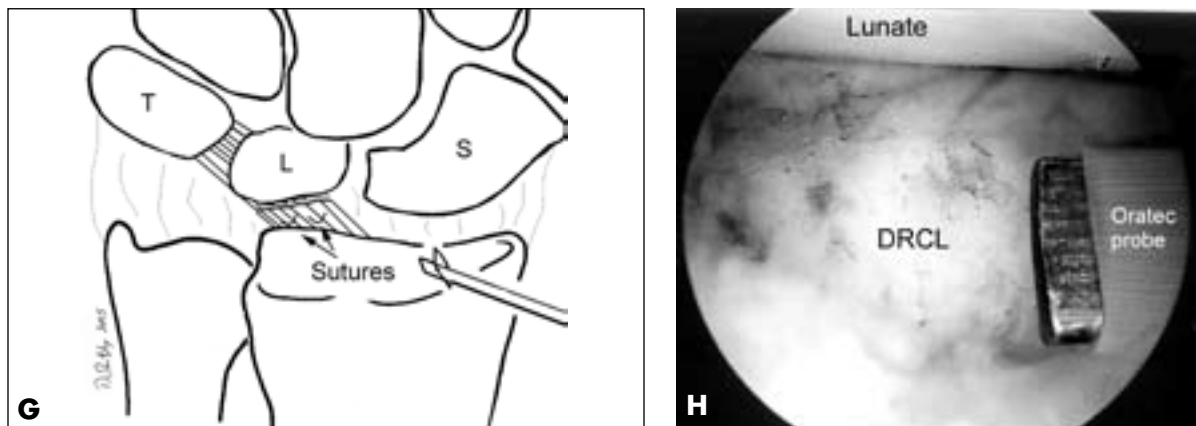


Figure 21. (continued)

Arthroscopic outside-in dorsal radiocarpal ligament (DRCL) repair. **G)** Drawing of completed repair. **H)** Repair augmented with thermal shrinkage after tying of suture. From Slutsky DJ. Arthroscopic repair of dorsal radiocarpal ligament tears. *Arthroscopy: The Journal of Arthroscopic and Related Surgery* 2005 Dec, 21 (12):1486e–1486e8; with permission.

Table 3. Arthroscopic Classification of Scapholunate Ligament (SLIL) Injury

Grade	Radiocarpal SLIL	Midcarpal Instability	Step-off
I	Hemorrhage of SLIL No attenuation	none	none
II	Incomplete partial or full substance tear No attenuation	slight gap (less than width of 3 mm probe)	Midcarpal only
III	Ligament attenuation Incomplete partial or small full substance tear	probe can be passed between carpal bones	Midcarpal and Radiocarpal
IV	Complete tear	Gross instability 2,7 mm arthroscope can be passed between SL gap (drive through sign)	Midcarpal and Radiocarpal
IV	Complete tear		

Adapted from Geissler WB, Freeland AE, Savoie F, et al. Intracarpal soft-tissue lesions associated with an intra-articular fracture of the distal end of the radius. *J Bone Joint Surg Am* 78:357–364, 1996.

to provide rapid joint irrigation in order to minimize the risk of chondral damage through heat necrosis. The probe is applied using multiple strokes like a paintbrush for only a few seconds at a time to prevent the joint temperature from rising.

In the midcarpal joint, the distal continuation of the RSC ligament (the radial limb or arcuate ligament) is seen at the volar junction of the scaphoid and lunate. Careful, limited,

short bursts of thermal energy to this tissue may tighten the scapholunate and scapho-luno-capitate articulations. When midcarpal examination reveals scapholunate joint congruency without gapping, the thermal shrinkage is complete.

Arthroscopic-assisted percutaneous K-wire fixation: Transarticular pinning has been hypothesized to precipitate a fibrous ankylosis that stabilizes the joint. In patients with partial tears without carpal malrotation, temporary K-wire

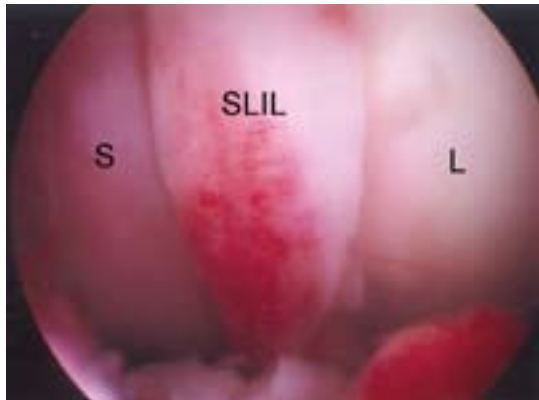

Figure 22.

Example of a Grade I scapholunate ligament (SLIL) injury as seen from the 3-4 portal. There is hemorrhage but no attenuation. S = scaphoid, L = lunate.

fixation may improve scapholunate stability. Whipple found that the best results were seen in patients with less than 3 months' symptom duration and a less than 3 mm side-to-side gap difference. Patients did poorly with chronic tears of > 3 months duration. The results are still suboptimal in chronic lesion even when combined with aggressive arthroscopic debridement down to bleeding bone.

The procedure is done under fluoroscopy. It is my preference to preposition the K-wire in a freehand manner by manually pushing it through the skin and lining it up against the waist of the scaphoid with the proper "angle of attack". Dorsal pressure is applied over the scaphoid tubercle along with radial wrist deviation which extends the scaphoid and closes the scapholunate gap. The K-wire is then driven across the SL joint. A second K-wire is inserted between the distal scaphoid and the capitate. The reduction is checked with both fluoroscopy and arthroscopy. If necessary, individual K-wires can be inserted in the lunate and the distal scaphoid and used as joysticks to derotate the scaphoid and lunate. The guidelines for pin placement in the snuffbox follow those of the 1-2 portal: In order to minimize the risk of injury to branches of the SRN or radial artery, the K-wires should be introduced in a safe zone that is no more than 4.5 mm dorsal to the 1st extensor compartment and within 4.5 mm of the radial styloid. Pinning can be performed with or without thermal shrinkage and combined with a DRCL repair.

Rehabilitation

Patients are splinted for comfort then started on wrist motion at 1 week. If a DRCL repair is performed the patient

is held in a short arm cast for 6 weeks, followed by wrist mobilization.

Lunotriquetral Ligament Injuries

Indications

Similar to SLIL injuries, arthroscopy is invaluable for the assessment and treatment of LTIL injuries. Hanker has modified Geissler's grading system and has proposed an algorithm of treatment based upon the arthroscopic findings (Table 4). LTIL ligament tears often coexist with TFCC tears and an ulna positive variance. An LTIL debridement may be combined as necessary with TFCC debridement and a wafer resection or an open ulnar shortening osteotomy.

Contraindications

Patients with static carpal instability may be staged arthroscopically, but they will usually require an open procedure for definitive treatment.

Surgical technique

The LTIL is seen obliquely from the 4-5 portal and often difficult to differentiate from the carpal bones without probing, unless a tear is present. Superior views of the LTIL can be obtained through the 6R and 6U portal. Volar tears of the LTIL are best seen through the VU portal, but can also be seen obliquely through the 6U portal. The 4-5 portal is the standard instrumentation portal. Midcarpal arthroscopy is necessary to grade any LT joint instability. Occasionally, tears of the ulnar limb of the arcuate ligament (i.e., the triquetro-hamate-capitate) are evident (Figure 23).

Treatment algorithm based upon stage—Grade 0: This is a stable LT ligamentous injury which is expected to heal with wrist immobilization. The prognosis for successful resolution of the wrist pain associated with a mild sprain is excellent.

Grade I: The LT ligament is intact with no attenuation of its fibers. There may be an incomplete partial or small full substance tear. There is no increased carpal movement between the lunate and triquetrum. The LT joint is congruent with no alteration of carpal kinematics. If a small ligamentous tear is present, it should be debrided. The wrist is immobilized for four to six weeks in a splint. The prognosis is excellent.

Grade II: There is significant attenuation of the LTIL. Often a partial or full substance incomplete tear of the volar and/or dorsal portions of the LTIL is present. More frequently there is a complete central membranous tear

Table 4. Hanker modification of Geissler classification for lunotriquetral interosseous ligament (LTIL) joint injuries (reference)

Grade	Radiocarpal LTIL	Instability	midcarpal incongruency
0	Hemorrhage of interosseous ligament No attenuation	none	none
I	Incomplete partial or full substance tear No attenuation	none	none
II	Ligament attenuation Incomplete partial or small full substance tear	predynamic or mild dynamic instability	mild
III	Complete tear	The joint is dynamically unstable	unstable but reducible
IV	Complete tear	Gross instability drive through sign	Marked joint incongruency static VISI

Adapted from Hanker GJ. Arthroscopic Treatment of Lunotriquetral Ligament Injuries. In *Techniques in Hand and Wrist Arthroscopy*. Slutsky DJ, Nagle DJ, eds. Philadelphia: Elsevier, Inc. In press.

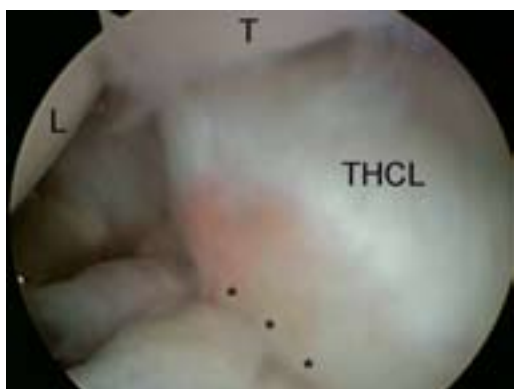

Figure 23.

View from the MCU portal demonstrating a tear of the triquetro-hamate-capitate ligament (THCL). With the torn edge (*) hanging over the lunotriquetral joint. L = lunate, T = triquetrum.

associated with stretching of the volar and dorsal portions of the LTIL. A *predynamic* instability characterized by cartilage wear and possible increased LT motion may be seen. Usually there is excessive scar tissue built up in the dorsoulnar aspect of the carpus, with synovitis. Hanker has reported good results with debridement of any partial or incomplete tears of the palmar and dorsal portions of the ligament, arthroscopic reduction, thermal LTIL shrinkage and percutaneous K-wire fixation for 8 weeks.

Grade III: There is a complete LTIL tear (Figure 24). The LT joint is clearly unstable when a force is applied, but the joint is reducible. A static LT diastasis is not present, and injury to the secondary restraint extrinsic ligaments is not seen. A probe can be passed through the LT gap. Grade 3 LTIL tears less than 6 months old are treated similar to grade II sprains. However, the outcomes of percutaneous fixation deteriorate in patients with injuries that are greater than 6 months old. In those instances, open treatment should be considered.

Grade IV: Acute grade IV LTIL injuries present with a severe alteration of carpal alignment, incongruency of the LT joint and gross instability. It is possible to manage these arthroscopically before a fixed VISI occurs if the LT joint is reducible. The triquetrum should also be pinned to the hamate for 8 weeks. A chronic grade IV LTIL injury usually requires open treatment.

Midcarpal Instability (MCI)

Indications

There are no arthroscopic findings that are diagnostic of midcarpal instability (MCI). Laxity of the LT ligament may be seen, though this is not invariable. Midcarpal arthroscopy may reveal laxity of the triquetrohamate-capitate ligament (THCL) but this is difficult to gauge. There may be an associated tear of the DRCL. Nonsurgical treatment consists of activity modification, NSAIDs and splinting.

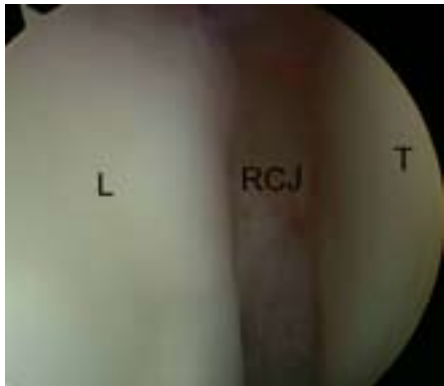

Figure 24.

View from the MCR demonstrating a complete Grade III instability of the lunotriquetral joint. Note how the radiocarpal joint (RCJ) can be seen through the large gap between the lunate (L) and triquetrum (T).

Various pisiform support splints have been described. Definitive treatment of this condition ultimately requires surgical treatment. Lichtman has performed an open dorsal capsular reefing in milder cases. Other soft tissue procedures have been described, including direct open repair of a dorsal radiocarpal ligament tear. Many authors recommend a midcarpal arthrodesis as the definitive long term solution for more severe cases. More recently, Culp has described an alternative treatment method which employs arthroscopic thermal shrinkage of the ulnar limb of the arcuate ligament. This technique has enjoyed some success for milder cases.

Surgical technique

Large bore outflow cannulas are desirable to provide rapid joint irrigation in order to minimize the risk of chondral damage through heat necrosis. The standard dorsal portals including a 3-4 and 4-5 portal are used for an arthroscopic survey. Any associated triangular fibrocartilage tears or lunotriquetral ligament tears are noted and treated by debridement or repair. The ulnar extrinsic ligaments are assessed for laxity. If laxity is noted, a 1.5 mm electrothermal probe (Oratec, Menlo Park, CA) is introduced through the 6R portal. The ulnolunate and ulnotriquetral ligaments are painted with the probe using a striping technique, leaving sections of untouched ligament in between. The correction of any associated volar intercalated segmental instability (VISI) deformity is assessed using a combination of arthroscopy and fluoroscopy.

Next, the midcarpal joint is viewed through the midcarpal radial portal. The scapholunate and lunotriquetral joints are inspected and probed for laxity. The THCL is identified as it runs obliquely from the triquetrum, across the proximal corner of the hamate to the palmar neck of the capitate. A midcarpal ulnar portal is established and used for introduction of the thermal probe. The THCL is then shrunk while again adjusting the tension with correction of any VISI deformity.

A volar radial portal is then established. If there is significant laxity of the DRCL, the probe is introduced through the 3-4 or 4-5 portal and used to shrink the DRCL, again in a striped fashion. The tension of the DRCL can be adjusted by correcting any VISI deformity with a K-wire in the lunate under fluoroscopic control. At the end of the procedure 0.045 mm K-wires are used to pin the triquetrum to the capitate and hamate in a neutral and reduced position. The patient is placed in a short arm cast. The cast and K-wires are removed at 4 weeks followed by home range of motion exercises and gradual strengthening.

Triangular Fibrocartilage Tears

Palmer proposed a classification system for triangular fibrocartilage complex (TFCC) injuries which differentiates between traumatic and degenerative lesions. TFCC tears can also be subdivided based upon the time that has elapsed from the injury. Acute tears are < 3 months, subacute tears are 3 months to 1 year and chronic tears are > 1 year. Arthroscopic repair of acute tears have the best prognosis and can result in the recovery of up to 85% of the contralateral grip strength and range of motion. Repair of subacute tears generally results in less return of strength and range of motion. Chronic tears (more than 1 year) are repairable but with inconsistent results.

Indications

Repairable peripheral tears of the TFCC are either Type 1B lesions, which are peripheral tears that occur as the ulnar side of the TFCC complex is avulsed from the ulnar capsule, or Type 1C lesions which involve a tear of the volar attachment of the TFCC or ulnocarpal ligaments.

Contraindications

This includes gross DRUJ instability, an arthritic radiocarpal joint and ulnocarpal abutment, which is usually treated with TFCC debridement and ulnar shortening or wafer resection.

Wrist Arthroscopy: Portals and Procedures

Surgical Technique—Repair of ulnar and central TFCC tears

A meniscal repair set (Smith and Nephew, Memphis, TN) or a TFCC repair kit (Linvatec, Largo, FL) can facilitate the procedure, but it may also be performed with a Tuohy needle and 18-gauge spinal needles.

The arthroscope is placed in the 3-4 portal and the 4-5 and/or 6R portals are used for instrumentation. I also use the volar ulnar (VU) portal for triangulation of the instruments and to allow better visualization of the dorsal ulnar corner of the TFCC. Any synovitis obscuring the view is debrided with a resector or thermal probe. The tear is identified. If the ulnar head is visible then there is either a radial (1D) or central (1A) tear (Figure 25A–B). The ulnar head is usually still covered with a peripheral tear (1B or 1C). If no tear is seen but there is a loss of TFCC tension a foveal detachment may be present. This diagnosis is made through either a small capsulotomy or an inspection of the deep insertion through the volar DRUJ portal. If present, a direct open foveal attachment is necessary.

Once a peripheral lesion is identified, it is debrided to provide a stimulus for fibrin clot formation at the repair site. A 22-gauge needle is placed into the wrist joint at the level of the tear. A 1.0 to 2.0 cm longitudinal dorsoular incision is then made centered over the needle (about the 6U portal) to avoid injury to the dorsal cutaneous branch of the ulnar nerve, which is identified and protected. Dissection is carried down to the wrist capsule. An outside-in technique is preferred, using either vertical or horizontal mattress sutures. An 18 gauge needle is passed just radial to the torn edge of the TFCC. The 2-0 PDS suture is then threaded into the 18-gauge needle and inserted into the wrist joint through via the ulnar sided incision under arthroscopic control. The intra-articular suture is retrieved with arthroscopic grasping forceps or a wire suture lasso through a separate puncture wound. The tissue bridge between the just inserted suture grasper and the 18 gauge needle is the area over which the repair will be tied down. Two or three sutures are passed and tied with the traction released.

Rehabilitation

The patient is placed in a long arm splint with the wrist in neutral for 4 weeks, followed by a short arm splint for an additional 2 weeks. After 6 weeks, passive range of motion exercises and gentle strengthening are instituted, with a return to full activities after approximately 10–12 weeks.

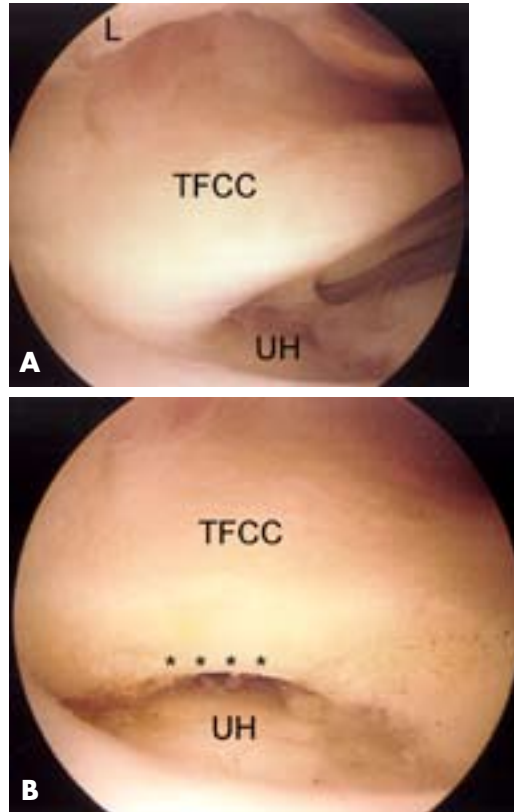


Figure 25.

TFCC tear. **A)** View of a central tear of the TFCC which is being held up by the probe, which exposes the ulnar head (UH). L = lunate. **B)** After debridement of the tear to a stable rim (*).

Surgical Technique—Repair of Radial TFCC tears

As with ulnar sided tears, it is important to first assess the stability of the DRUJ. Most acute tears are treated with immobilization for 4 weeks. A failure to respond to non-operative management is an indication for surgical treatment. Isolated radial sided tears with a stable DRUJ may be treated by arthroscopic debridement, with results equal to those following repair (L. Osterman, International Wrist Investigators workshop, New York, 2004). Those with DRUJ instability may require repair.

Repair: The scope is placed in the 4-5 portal or the VU portal. The tear is debrided back to stable edges. A curet or burr is then used to roughen the sigmoid notch at the proposed repair site. An arthroscopic cannula is inserted through the 6U portal. Under direct vision a 2.5 mm drill bit is advanced through the cannula and into the sigmoid notch, aiming towards the radial metaphysis. Two separate

drill holes are made. A double-armed meniscal repair needle with 2-0 absorbable suture is then placed through the canula. The needles penetrate the radial TFCC approximately 5 mm from the edge of the tear and are then advanced through the separate drill holes to be brought out through the proximal and radial side of the wrist. A small skin incision is made between the first and second compartment to retrieve the sutures and protect the superficial radial nerve. The sutures are then tied over the periosteum of the distal radius with the wrist traction released. The repair is inspected arthroscopically and additional sutures are placed if the repair requires reinforcement. The patient is immobilized in a Munster splint allowing elbow flexion but restricting forearm rotation for 4 weeks, followed by wrist mobilization.

Arthroscopic Wafer Resection of the Distal Ulna Indications

The main indication is that of chronic ulnar sided wrist pain for ulnar abutment (impaction) syndrome. In ulnar abutment there is a triad of an LT ligament tear, a TFCC tear and an ulna neutral or ulnar positive variance. In this case, the articular disc is pinched between the ulnar head and the proximal surface of the lunate especially with ulnar deviation and loading of the wrist. Feldon et al. demonstrated favorable results with an open wafer resection of the distal ulna. Tomaino reported good results with an arthroscopic TFCC disc excision and wafer resection for the treatment of ulnar abutment before a TFCC tear has occurred.

Contraindications

Osteoarthritis of the ulnar head and DRUJ instability are relative contraindications. Any associated LTIL instability needs to be addressed separately.

Surgical Technique

The arthroscope is placed in the 4-5 portal. The 6R and 6U portals are used mainly for instrumentation, although it may be helpful to view the completeness of ulnar head resection through the 6U portal as well (Figure 26A–B). The VU portal may be used for viewing while the burr is placed in the 4-5 or 6R dorsal portals, since this increases the space available for the triangulation of instruments (Figure 27). Rapid irrigation is needed to clear the debris. The edges of the TFCC tear are debrided back to stable margins. A 2.9 mm burr is then used in a back and forth motion to resect 2–3 mm of the ulnar head. The diameter of the burr can be

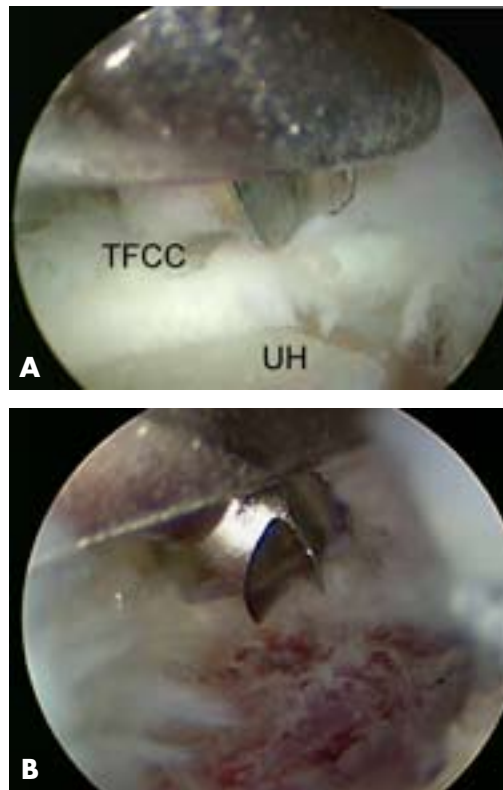


Figure 26.

A) View of the ulnar head (UH) from the VU portal. The TFCC has been debrided back to a stable edge. **B)** After resection of 2 mm of the ulnar head.

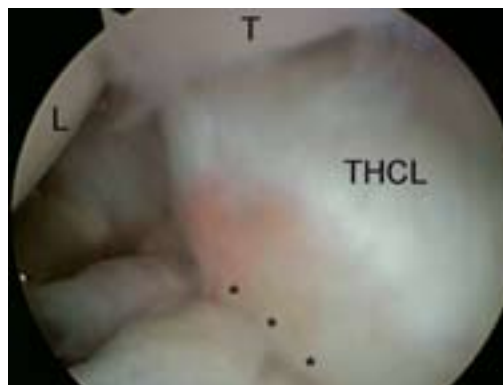

Figure 27.

View from the VU portal in ulnar impaction. A probe in the 4-/5 portal is pushing down the marked synovitis of the dorsoulnar capsule. DRUL = dorsal radioulnar ligament, T = triquetrum.

Wrist Arthroscopy: Portals and Procedures

used as a gauge of the amount of bony resection, but this should also be checked fluoroscopically. The arm must be pronated and supinated in order to avoid leaving a shelf of bone. Care must be taken to avoid injury to the deep foveal insertion of the TFCC as well as the sigmoid notch. The goal is to resect sufficient ulna to produce a 2 mm negative ulnar variance.

The burr may also be placed underneath the TFCC in the distal dorsal DRUJ portal, if needed. Use of the volar DRUJ portal may allow visualization of the distal ulna in cases with an intact articular disc. The VDRUJ portal is also useful for assessing the completeness of a wafer resection, since it is often difficult to resect the ulnar dome completely through a TFC perforation without extreme pronation and supination of the forearm combined with artful maneuvering of the arthroscope.

Rehabilitation

Early wrist motion including pronation and supination are instituted in the first week. If there is difficulty regaining supination, the patient can be immobilized in supination in a long arm splint in between range of motion exercises. Dynamic splinting is started after 4–6 weeks if needed.

Arthroscopic Assisted Fixation: Distal Radius Fractures

Indications

Displaced intra articular fractures of the distal radius are often associated with unrecognized intra-articular soft tissue injuries, which may influence the outcome. More than 2 mm of articular displacement or gap are typical indications for surgical treatment. Isolated radial styloid fractures and simple 3-part fractures are most suited to arthroscopic technique. Four-part fractures should be attempted only after one has gained experience with simpler fracture patterns.

Contraindications

Large capsular tears which carry the risk of marked fluid extravasation, active infection, neurovascular compromise and distorted anatomy are contraindications. Marked metaphyseal comminution, shear fractures and a volar rim fractures require open treatment, although the arthroscope may be inserted to check the adequacy of intra-articular reduction.

Surgical Technique

Intraoperative fluoroscopy is used frequently throughout the case, with the C-arm positioned horizontal to the floor.

The unit is moved in and out as needed throughout the case. Geissler recommends delaying surgery until 3–10 days after the initial intra-articular bleeding has stopped. I have found it useful to perform much of the procedure without fluid irrigation using the dry technique of del Pinal, which eliminates concerns regarding fluid extravasation. Occasional irrigation along with joint suctioning keeps the field clear. If fluid irrigation is used, the initial fracture lavage can be performed without tourniquet in order to save tourniquet time. My preference is to use a large bore inflow cannula in the 4-5 or 6U portal. Outflow is through the arthroscope's cannula. The working portals include the volar radial and 6R portal for fracture visualization and the 3-4 portal for instrumentation. However, all of the portals are used interchangeably. Lactated Ringer's solution is preferred over saline and the forearm is wrapped with coban to limit extravasation.

Due to the associated swelling and distorted anatomy it is helpful to locate the portals with a 22-gauge needle in order to avoid further joint injury. The fracture hematoma and debris are washed out to improve visualization and any early granulation tissue is debrided with a resector. Freer elevators and curets can also be used by enlarging the portals. Bain and colleagues described a 5-level algorithm for reducing the fracture fragments. This included the "London technique" for comminuted intra-articular fractures where the K-wires were advanced through the distal ulna into the subchondral distal radius and withdrawn from the radial aspect so that they did not encroach on the distal radioulnar joint.

Radial styloid fractures: Reduction is easiest to obtain using ligamentotaxis while the arm is suspended in traction. A freer elevator placed through the 3-4 portal and into the fracture site may help with fracture manipulation. A 1 cm incision is made over the styloid to prevent injury to the superficial radial nerve, and two 0.62 mm K-wires are inserted for manipulation of the styloid fragment. The fracture is best assessed by viewing across the wrist with the arthroscope in the 6R portal, in order to judge the rotation of the styloid. Along with the freer, the K-wire joysticks are used to manipulate the fragment. Once reduction is obtained, the K-wires are driven forward to secure the reduction. The positions of the guide wires are then checked under fluoroscopy. Cannulated screws may be placed over the guide wires to provide increased stability.

Three-part fractures: Three-part fractures are comprised of a radial styloid fragment and a lunate facet frag-

ment. The radial styloid fracture is reduced and pinned as above. This fragment is then used as a landmark to which the depressed lunate facet fragment is reduced. The depressed lunate facet fragment is viewed through the 3-4 portal. A 22-gauge needle may be percutaneously placed on the surface of the depressed fragment to use as a landmark so that a large Steinmann pin can be placed approximately two centimeters proximal to the 18-gauge needle, under the depressed lunate facet fragment. The Steinman pin is then used to elevate the lunate facet fragment. Once the lunate facet fragment is reduced to the radial styloid fragment, a large tenaculum forceps is used to maintain the reduction. The curve of the forceps should be quite large to prevent crushing the superficial radial nerve. The tips of the forceps may be placed directly against the ulna to facilitate this step. Horizontal subchondral guide wires are then inserted, stopping short of the DRUJ. The forearm is rotated to check for crepitus to ensure that the transverse pins have not violated the distal radioulnar joint, since this may not be evident fluoroscopically. If a dorsal die punch fragment is present, it is important that the guide pins are aimed dorsally to capture this fragment. In this case, use of the volar radial portal allows superior views of this dorsal fragment. The metaphyseal defect is bone grafted through a small dorsal incision to prevent late collapse.

Once the reduction has been achieved, some type of neutralization device is desirable. Reported devices have included bridging external fixators, volar locking plates and headless cannulated screws. In many instances, the author's preference is a non-bridging external fixator, with or without a dorsal outrigger (The Fragment Specific Fixator, South Bay Hand Surgery, LLC, Torrance, CA).

Four-part fractures: In four-part fractures, the lunate facet is separated into volar and dorsal fragments. The volar-ulnar fragment usually requires open reduction, as traction on the volar wrist capsule rotates it, preventing reduction by closed manipulation. If one desires to combine arthroscopic and open reduction, the radial styloid fragment is reduced and fixed as above. The volar-ulnar fragment is then reduced through an open volar approach. Options include the standard approach through the flexor carpi radialis tendon sheath, or an approach between the flexor tendons and ulnar neurovascular bundle. The reduction may be confirmed by arthroscopic visualization through the 6R and volar-radial portals. Following reduction, a 2.7 mm volar locking plate is used for fixation (Figure 28A–M).

The dorsal-ulnar fragment is then percutaneously elevated back to the radial styloid and volar-ulnar fragment. For fixation, a small locking dorsal plate can be applied, or alternatively the distal screws of the volar plate may be used to hold the volar-ulnar and dorsal-ulnar fragments. The first screw should be placed in a non-locking fashion to help lag the fragments, followed by supplemental locking screws.

Ulnar styloid fractures: If the articular disc is lax by palpation, a peripheral tear of the triangular fibrocartilage complex is suspected. Any peripheral TFCC tears are repaired arthroscopically using the outside-in technique described above and the styloid fracture is ignored. If the TFCC remains well attached, however, consideration should be given to open fixation of a large ulnar styloid fragment.

Arthroscopic-assisted, Percutaneous Fixation of Scaphoid Fractures

Indications

The indications are similar to those for an open reduction. This includes any acute displaced proximal pole or waist fracture of the scaphoid with > 1 mm of displacement or translation, or any fractures with significant comminution or angulation. Distal pole fractures have a better prognosis and are often successfully treated with casting. Recent studies have demonstrated 100% union rates which has spurred some to recommend internal fixation of any undisplaced scaphoid fracture in selected populations. This issue requires further study however. Undisplaced fibrous scaphoid nonunions without evidence of avascular necrosis are also suitable candidates provided there are no radiocarpal or midcarpal degenerative changes.

While screw placement may appear acceptable on x-ray, arthroscopy allows the surgeon to determine if there is any screw cutout medially and whether the proximal screw is buried deeply enough to avoid prominence in the radiocarpal joint. The stability of fixation may also be assessed by palpating the fracture/nonunion site following screw insertion, which will help determine whether K-wire augmentation is needed. Any associated interosseous ligament injuries or other carpal injuries can also be assessed.

Contraindications

Partial or complete avascular necrosis of the scaphoid is a relative contraindication to percutaneous techniques, although this has also been successfully managed arthroscopically. Nonunions with a humpback deformity and secondary DISI

Wrist Arthroscopy: Portals and Procedures

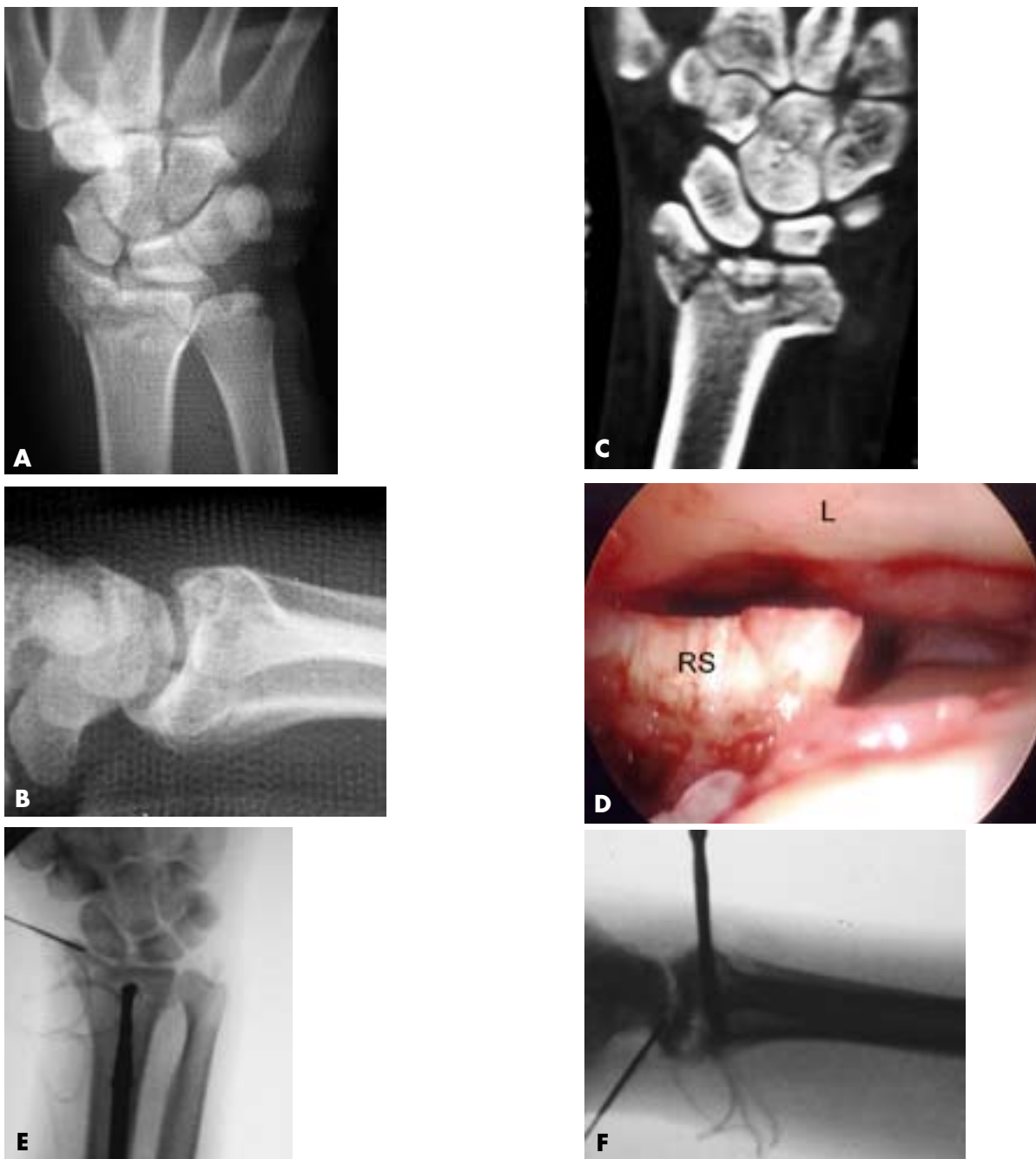


Figure 28.

Arthroscopic Guided Fixation of Intra-articular Distal Radius Fracture. **A)** AP view of a comminuted intra-articular radius fracture. **B)** Lateral view showing the dorsal tilt and articular disruption. **C)** CT view highlights the extent of articular comminution. **D)** View from the 6R portal using the dry technique. RS = radial styloid, L = lunate. **E)** Percutaneous elevation of depressed articular fragments. **F)** Percutaneous correction of dorsal tilt.

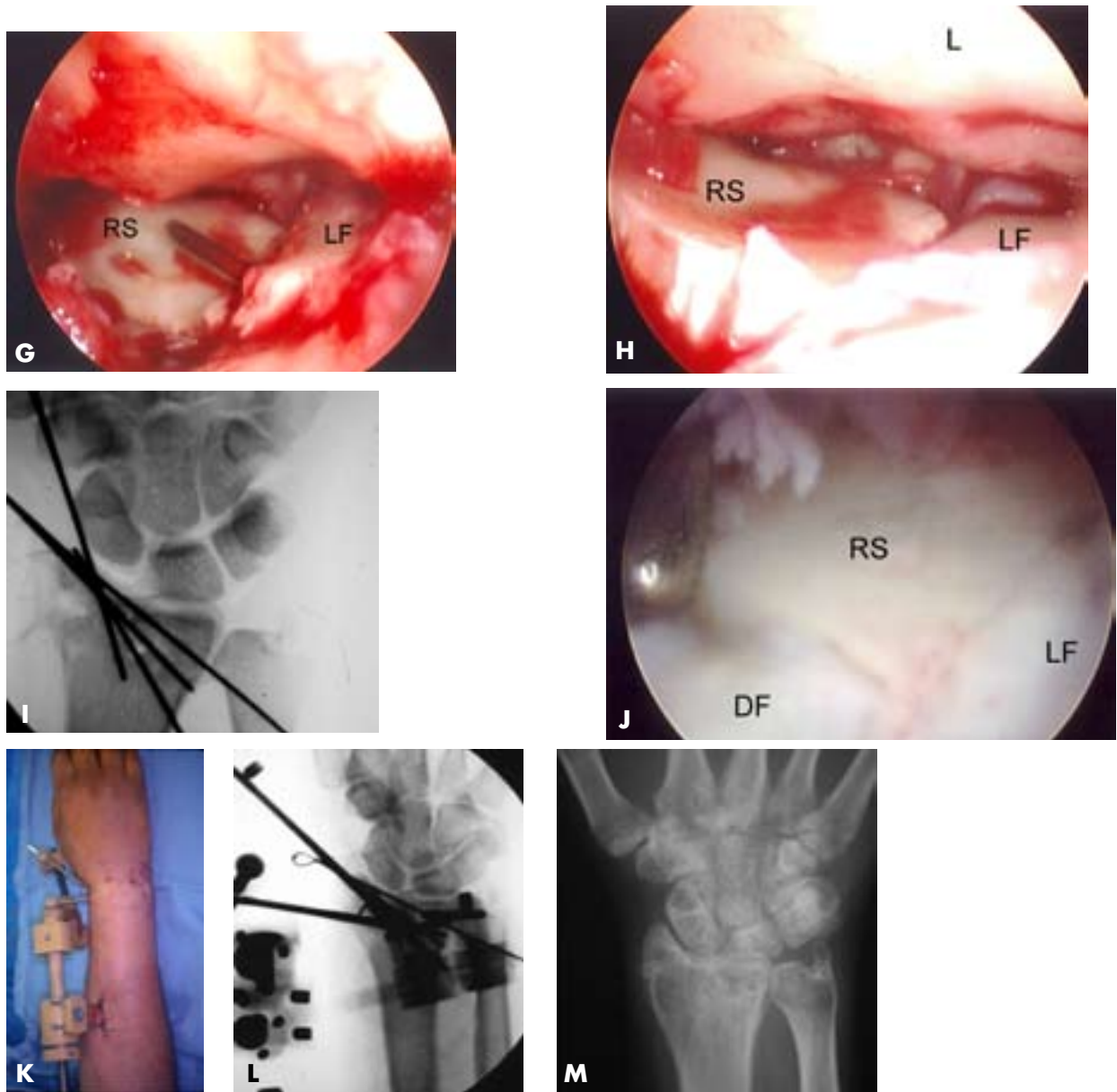


Figure 28. (continued)

G) Positioning of percutaneous pin inserted through the ulna (London technique). **H)** After pinning of lunate fragment (LF) to radial styloid fragment. **I)** After arthroscopic reduction and percutaneous pinning. Note restoration of radial tilt. **J)** Arthroscopic view demonstrating a congruent joint surface (DF = dorsal fragment). **K)** Application of nonbridging external fixator. **L)** Intraoperative view with nonbridging fixator. **M)** After removal of fixator at 6 weeks.

Hand Surgery Update

Wrist Arthroscopy: Portals and Procedures

deformity require an open volar wedge graft. The presence of significant radiocarpal and/or midcarpal degenerative also mandate an alternate approach.

Set-up

The ideal setup utilizes a mini-fluoroscopy unit and the ARC traction tower (ARC medical, Portland Oregon), which greatly facilitates switching between fluoroscopy and arthroscopy. If the guide wire is inserted dorsally, the wrist is flexed approximately 45 degrees in a pronated position over the attached forearm block and the patient's hand is suspended in finger traps with 10–15 lbs. of traction. The gantry of the mini-fluoro unit is also positioned at a 45 degree angle from vertical, which places the beam at 90 degrees to the carpus. PA, oblique and lateral views are then easily obtained by rotating the forearm. The guide wires may also be left protruding both proximally and distally without disturbing the position of the wrist while switching between arthroscopy and fluoro.

If the ARC tower is unavailable, any type of traction will suffice. In this case, it is necessary to keep the wrist flexed if the guide wire is inserted dorsally, but then to withdraw the guide wires distally to suspend the wrist in traction in order to take x-rays or insert an arthroscope, which becomes quite tedious.

Surgical Technique

Guide wire insertion is accomplished fluoroscopically. Following guide wire insertion, the arm is suspended in

traction and the reduction is visualized through the MCU portal with the probe in the MCR portal. Other carpal injuries are identified and treated. Following arthroscopy, the wrist is taken out of traction and an appropriate-sized screw placed. If desired, percutaneous iliac bone graft harvested with a bone biopsy needle or demineralized bone matrix can be injected percutaneously by advancing the arthroscopic cannula down the guide wire and into the drill hole in the proximal scaphoid, prior to screw insertion (Figure 29A–L).

Following screw insertion, the fracture / non-union site is again inspected arthroscopically. If rigid fixation has not been achieved, Slade has recommended pinning the distal fragment to the capitate to lock the midcarpal row and reduce fracture site motion. This is especially helpful in fractures with short proximal or distal fragments where only a few screw threads engage the fragment.

Summary

Advances in wrist arthroscopy continue to expand the indications and treatment options for myriad wrist disorders. A systematic approach and a thorough understanding of the topographical and internal anatomy of the wrist are integral to minimizing complications while maximizing the chances for a successful outcome.

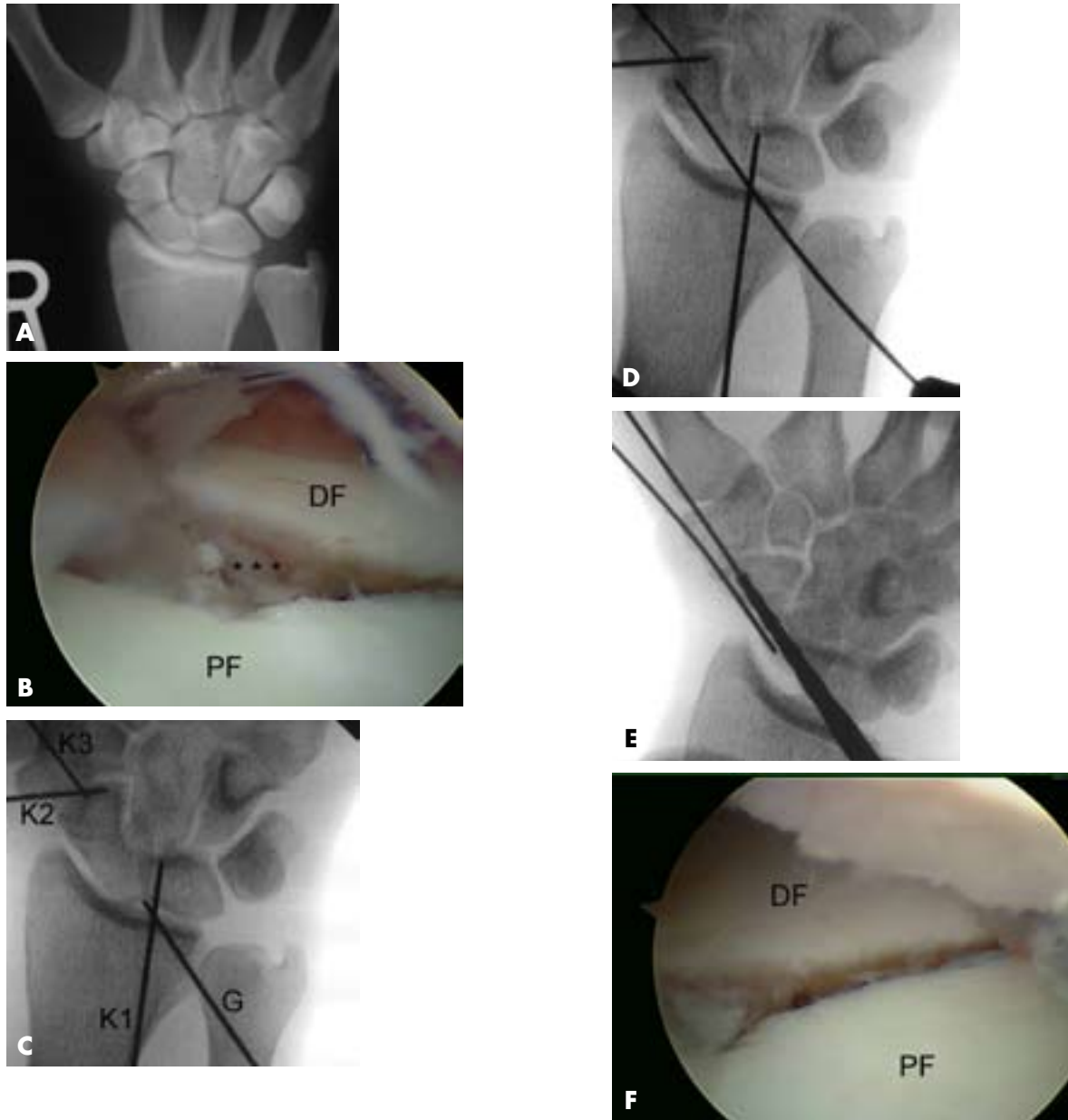


Figure 29. (continued on next page)

Arthroscopic Guided Fixation of Acute Scaphoid Fracture. **A)** AP view of a scaphoid waist fracture with central comminution. **B)** Arthroscopic view from the MCU showing the distal fragment (DF) and proximal scaphoid fragment (PF). **C)** Starting point for guide (G) wire insertion at proximal scaphoid pole. Note the targeting K-wires at the SL gap (K1), and the scaphotrapezial joint (K2, K3). **D)** Advancement of guide wire down central scaphoid axis. **E)** Semi-pronated view showing reaming stops 2 mm short of scaphotrapezial joint. Note the 2nd anti-rotation wire. **F)** Arthroscopic view after screw implantation. There was improvement in the fracture gap, but the distal fragment was still freely moveable to palpation.

Wrist Arthroscopy: Portals and Procedures

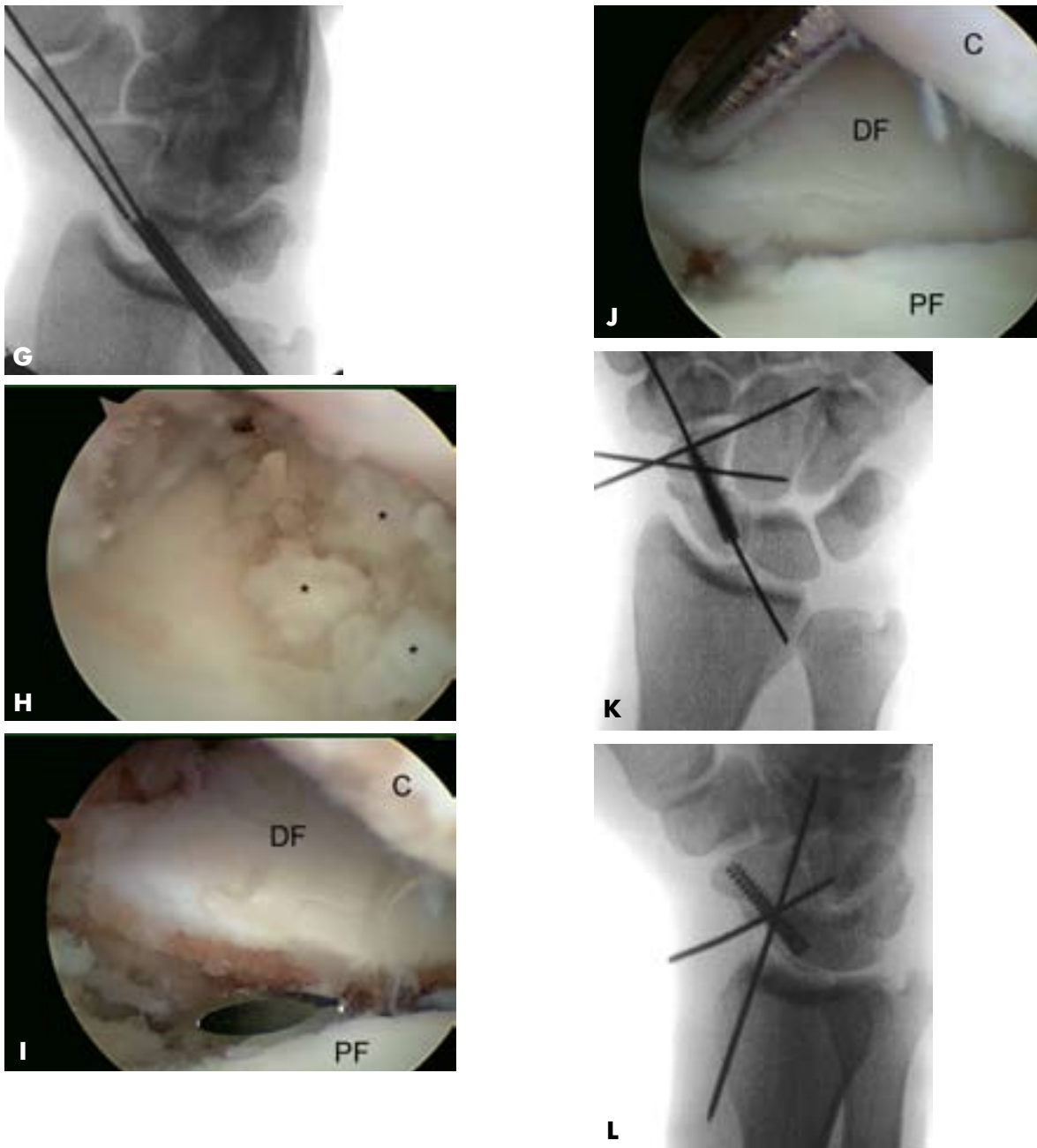


Figure 29. (continued)

Arthroscopic Guided Fixation of Acute Scaphoid Fracture. **G)** Screw was removed and demineralized bone matrix (DBM) was injected through the arthroscopic cannula. **H)** MCU view demonstrating that the DBM (*) filled the fracture site. **I)** Percutaneous 22-gauge needle used to localize the comminuted segment. C = capitate. **J)** Rigid fixation after arthroscopic pinning of comminuted segment to capitate. Note the improvement in the fracture gap. **K)** AP view after repeat screw fixation. **L)** Mid-pronated view after guide wire removal.

SELECTED READINGS

Darlis NA, Weiser RW, Sotereanos DG. Partial scapholunate ligament injuries treated with arthroscopic debridement and thermal shrinkage. *J Hand Surg [Am]* 2005;30:908–14.

Sixteen patients with chronic dorsoradial wrist pain underwent debridement and thermal shrinkage of a symptomatic partial SLIL injury (Geissler grades I and II). At short-term follow-up, there were 8 excellent, 6 good, 1 fair, and 1 poor result. The authors concluded that SLIL debridement and thermal shrinkage effectively provided pain relief for most of the patients treated, but cautioned that longer follow-up was necessary.

Slade 3rd JF, Gutow AP, Geissler WB. Percutaneous internal fixation of scaphoid fractures via an arthroscopically assisted dorsal approach. *J Bone Joint Surg Am* 2002; 84-A Suppl 2:21–36.

One hundred percent of twenty-seven scaphoid fractures (seventeen waist fractures and ten proximal pole fractures) treated with arthroscopically assisted dorsal percutaneous had united by an average of twelve weeks. In this series, the fractures that were treated early (less than one month after the injury) healed more quickly than those treated later.

Slutsky D. Arthroscopic repair of dorsoradiocarpal ligament tears. *The Journal of Arthroscopic and Related Surgery* 2005;21:1486e1–1486e8.

This paper reviews the results of arthroscopic DRCL repair in 56 wrists with a mean follow-up of 16 months. The 4 patients who underwent repair of an isolated DRCL tear had excellent results with no or mild residual pain. The presence of a DRCL tear in combination with a scapholunate, lunotriquetral, or TFC tear was associated with a poorer prognosis following treatment.

Slutsky DJ. Clinical applications of volar portals in wrist arthroscopy. *Techniques in Hand and Upper Extremity Surgery*. Vol 8, No 4, December 2004 pp. 229–238.

The volar radial portal is relatively easy to use and is ideal for evaluation of the DRCL and the volar aspect of the SLIL. The volar midcarpal portal may be considered as an occasional accessory portal for visualizing the volar aspects of the capitate and hamate in cases of avascular necrosis or osteochondral fracture. The volar ulnar portal is useful for the viewing and debridement of volar tears of the LTIL.

Trumble TE, Gilbert M, Vedder N. Arthroscopic repair of the triangular fibrocartilage complex. *Arthroscopy* 1996;12:588–597.

Twenty-two wrists underwent arthroscopic TFC repair, with mean 36 month follow-up. Postoperative range of motion averaged 86±9% of the contralateral side and grip strength averaged 82±20% of the contralateral side. There was a significant correlation between the delay from injury to surgical repair and final motion and grip strength.

REFERENCES

Abe Y, Doi K, Hattori Y, Ikeda K, Dhawan V. Arthroscopic assessment of the volar region of the scapholunate interosseous ligament through a volar portal. *J Hand Surg [Am]* 2003;28:69–73.

Abrams RA, Petersen M, Botte MJ. Arthroscopic portals of the wrist: an anatomic study. *J Hand Surg [Am]* 1994;19:940–944.

Ashwood N, Bain GI. Arthroscopically assisted treatment of intraosseous ganglions of the lunate: a new technique. *J Hand Surg [Am]* 2003;28:62–68.

Bain GI RR, Roth JH. Wrist Arthroscopy. In Lichtman DM AA, ed. *The Wrist and Its Disorders*. Philadelphia: WB Saunders, 1997:151–168.

Bain GI VR, Pederini L. Procedure artroscopiche capsulari del polso. In Pederini L, ed. *In Ortopedia E Chirurgia Mini-invasiva*. Springer-Verlag, 1999.

Balogh B, Valencak J, Vesely M, et al. The nerve of Henle: an anatomic and immunohistochemical study. *J Hand Surg [Am]* 1999;24:1103–1108.

Berger RA. Arthroscopic anatomy of the wrist and distal radioulnar joint. *Hand Clin* 1999;15:393–413, vii.

Bindra R. Arthroscopic Dorsal Wrist Ganglionectomy. In Slutsky DJ ND, ed. *Techniques in Hand and Wrist Arthroscopy*. Philadelphia: Elsevier, Inc, 2007.

Bond CD, Shin AY, McBride MT, Dao KD. Percutaneous screw fixation or cast immobilization for nondisplaced scaphoid fractures. *J Bone Joint Surg Am* 2001;83-A:483–438.

Botte MJ, Cohen MS, Lavernia CJ, et al. The dorsal branch of the ulnar nerve: an anatomic study. *J Hand Surg [Am]* 1990;15:603–607.

Bowers WH WT. Arthroscopic Anatomy of the Wrist. In McGinty J, ed. *Operative Arthroscopy*. New York: Raven Press, 1991:613–23.

Darlis NA, Kaufmann RA, Giannoulis F, Sotereanos DG. Arthroscopic debridement and closed pinning for chronic dynamic scapholunate instability. *J Hand Surg [Am]* 2006;31:418–424.

Darlis NA, Weiser RW, Sotereanos DG. Partial scapholunate ligament injuries treated with arthroscopic debridement and thermal shrinkage. *J Hand Surg [Am]* 2005;30:908–914.

DaSilva MF, Moore DC, Weiss AP, Akelman E, Sikiirica M. Anatomy of the palmar cutaneous branch of the median nerve: clinical significance. *J Hand Surg [Am]* 1996;21:639–643.

Wrist Arthroscopy: Portals and Procedures

- del Piñal F. Correction of Malunited Intra-articular distal radius fractures with an inside-out osteotomy technique. In Slutsky DJ, Nagel DJ, eds. *Techniques in Hand and Wrist Arthroscopy*. Philadelphia: Elsevier, Inc., 2007 (in Press).
- Dodds SD, Panjabi MM, Slade JF 3rd. Screw fixation of scaphoid fractures: a biomechanical assessment of screw length and screw augmentation. *J Hand Surg [Am]* 2006;31:405–413.
- Doi K, Hattori Y, Otsuka K, Abe Y, Yamamoto H. Intra-articular fractures of the distal aspect of the radius: arthroscopically assisted reduction compared with open reduction and internal fixation. *J Bone Joint Surg Am* 1999;81:1093–1110.
- Dumontier C, Meyer von Reckendorf G, Sautet A, et al. Radiocarpal dislocations: classification and proposal for treatment. A review of twenty-seven cases. *J Bone Joint Surg Am* 2001;83-A:212–218.
- Feldon P, Terrono AL, Belsky MR. Wafer distal ulna resection for triangular fibrocartilage tears and/or ulna impaction syndrome. *J Hand Surg [Am]* 1992;17:731–737.
- Garcia-Elias M, An KN, Cooney WPD, Linscheid RL, Chao EY. Stability of the transverse carpal arch: an experimental study. *J Hand Surg [Am]* 1989;14:277–282.
- Geissler W. The Role of Wrist Arthroscopy in the Management of Intra-articular Distal Radius Fractures. In Slutsky DJ ND, ed. *Techniques in Hand and Wrist Arthroscopy*. Philadelphia: Elsevier, Inc., 2007.
- Geissler WB. Intra-articular distal radius fractures: the role of arthroscopy? *Hand Clin* 2005;21:407–416.
- Geissler WB, Freeland AE. Arthroscopic management of intra-articular distal radius fractures. *Hand Clin* 1999;15:455–465, viii.
- Geissler WB, Freeland AE, Savoie FH, McIntyre LW, Whipple TL. Intra-articular soft-tissue lesions associated with an intra-articular fracture of the distal end of the radius. *J Bone Joint Surg Am* 1996;78:357–365.
- Gelberman RH, Panagis JS, Taleisnik J, Baumgaertner M. The arterial anatomy of the human carpus. Part I: The extraosseous vascularity. *J Hand Surg [Am]* 1983;8:367–375.
- Greenberg J. Arthroscopic Treatment of Volar Carpal Ganglion Cysts. In Slutsky D, Nagel DJ, ed. *Techniques in Hand and Wrist Arthroscopy*. Philadelphia: Elsevier, Inc., 2007.
- Goldfarb CA, Stern PJ, Kieffhaber TR. Palmar midcarpal instability: the results of treatment with 4-corner arthrodesis. *J Hand Surg [Am]* 2004;29:258–263.
- Harley BJ, Werner FW, Boles SD, Palmer AK. Arthroscopic resection of arthrosis of the proximal hamate: a clinical and biomechanical study. *J Hand Surg [Am]* 2004;29:661–667.
- Hanker G. Arthroscopic Treatment of Lunotriquetral Ligament Injuries. In Slutsky DJ ND, ed. *Techniques in Hand and Wrist Arthroscopy*. Philadelphia: Elsevier, Inc., 2007.
- Harley BJ PA. Arthroscopic Resection of Arthrosis of the Proximal Hamate. In Slutsky DJ ND, ed. *Techniques in Hand and Wrist Arthroscopy*. Philadelphia: Elsevier, Inc., 2007.
- Hausman M. Arthroscopic Reduction and Association of the Scaphoid and Lunate. In Slutsky DJ ND, ed. *Techniques in Hand and Wrist Arthroscopy*. Philadelphia: Elsevier, Inc., 2007.
- Horii E, Garcia-Elias M, An KN, et al. A kinematic study of luno-triquetral dissociations. *J Hand Surg [Am]* 1991;16:355–362.
- Ishii S, Palmer AK, Werner FW, Short WH, Fortino MD. An anatomic study of the ligamentous structure of the triangular fibrocartilage complex. *J Hand Surg [Am]* 1998;23:977–985.
- Levy HJ, Glickel SZ. Arthroscopic assisted internal fixation of volar intra-articular wrist fractures. *Arthroscopy* 1993;9:122–124.
- Lichtman DM, Culp RW, Joshi A. Palmar Midcarpal Instability. In E M, ed. *Operative Arthroscopy*. 3rd ed. Philadelphia: Lippincott Williams & Wilkins, 2003:737–742.
- Lichtman DM CR, Wroten ES, Slutsky DJ. The Role of Arthroscopy in Midcarpal Instability. In Slutsky DJ ND, ed. *Techniques in Hand and Wrist Arthroscopy*. Philadelphia: Elsevier, Inc., 2007.
- Lichtman DM, Wroten ES. Understanding midcarpal instability. *J Hand Surg [Am]* 2006;31:491–498.
- Mackinnon SE, Dellon AL. The overlap pattern of the lateral antebrachial cutaneous nerve and the superficial branch of the radial nerve. *J Hand Surg [Am]* 1985;10:522–526.
- Martin CH, Seiler JG, 3rd, Lesesne JS. The cutaneous innervation of the palm: an anatomic study of the ulnar and median nerves. *J Hand Surg [Am]* 1996;21:634–638.
- McCabe SJ, Kleinert JM. The nerve of Henle. *J Hand Surg [Am]* 1990;15:784–788.
- McCallister WV, Knight J, Kaliappan R, Trumble TE. Central placement of the screw in simulated fractures of the scaphoid waist: a biomechanical study. *J Bone Joint Surg Am* 2003;85-A:72–77.
- Mehta JA, Bain GI, Heptinstall RJ. Anatomical reduction of intra-articular fractures of the distal radius. An arthroscopically-assisted approach. *J Bone Joint Surg Br* 2000;82:79–86.
- Moritomo H, Viegas SF, Elder KW, et al. Scaphoid nonunions: A 3-dimensional analysis of patterns of deformity. *J Hand Surg [Am]* 2000;25A:520–528.
- Moskal MJ, Savoie FH, 3rd, Field LD. Arthroscopic capsulodesis of the lunotriquetral joint. *Clin Sports Med* 2001;20:141–153, ix–x.
- Nakamura T, Cooney WP, 3rd, Lui WH, et al. Radial styloidectomy: a biomechanical study on stability of the wrist joint. *J Hand Surg [Am]* 2001;26:85–93.
- Omokawa S, Ryu J, Tong JB, Han J. Vascular and neural anatomy of the thenar area of the hand: its surgical applications. *Plast Reconstr Surg* 1997;99:116–121.
- Osterman AL CR, Bednar JM. *The Arthroscopic Release of Wrist Contracture*. 2000.
- Osterman AL, Raphael J. Arthroscopic resection of dorsal ganglion of the wrist. *Hand Clin* 1995;11:7–12.
- Palmer AK. Triangular fibrocartilage complex lesions: a classification. *J Hand Surg [Am]* 1989;14:594–606.
- Palmer AK, Werner FW, Murphy D, Glisson R. Functional wrist motion: a biomechanical study. *J Hand Surg [Am]* 1985;10:39–46.
- Rosenwasser MP, Miyasaka KC, Strauch RJ. The RASL procedure: reduction and association of the scaphoid and lunate using the Herbert screw. *Tech Hand Up Extrem Surg* 1997;1:263–272.
- Rosenwasser MP GS, Riansuwan K. Arthroscopic Treatment of Scapholunate Ligament Tears. In Slutsky DJ ND, ed. *Techniques in Hand and Wrist Arthroscopy*. Philadelphia: Elsevier, Inc., 2007.
- Schoenecker PL, Gilula LA, Shively RA, Manske PR. Radiocarpal fracture-dislocation. *Clin Orthop Relat Res* 1985;237–244.

Wrist Arthroscopy: Portals and Procedures

- Siegel DB, Gelberman RH. Radial styloidectomy: an anatomical study with special reference to radiocarpal intracapsular ligamentous morphology. *J Hand Surg [Am]* 1991;16:40–44.
- Slade JF 3rd, Dodds SD. Minimally invasive management of scaphoid nonunions. *Clin Orthop Relat Res* 2006;445:108–119.
- Slade JF 3rd, Gutow AP, Geissler WB. Percutaneous internal fixation of scaphoid fractures via an arthroscopically assisted dorsal approach. *J Bone Joint Surg Am* 2002;84-A Suppl 2:21–36.
- Slade JF 3rd, Jaskwicz D. Percutaneous fixation of scaphoid fractures. *Hand Clin* 2001;17:553–574.
- Slutsky DJ. Arthroscopy Portals: Volar and Dorsal. In Trumble TE, Budoff JE ed. *Wrist and Elbow Reconstruction & Arthroscopy*. Rosemont, IL: American Society for Surgery of the Hand, 2006.
- Slutsky DJ. Arthroscopic repair of dorsal radiocarpal ligament tears. *Arthroscopy* 2002;18:E49.
- Slutsky D. Arthroscopic Repair of Dorsoradiocarpal Ligament Tears. *The Journal of Arthroscopic and Related Surgery* 2005;21:1486e1–1486e8.
- Slutsky DJ. Clinical Applications of Volar Portals in Wrist Arthroscopy. *Techniques in Hand and Upper Extremity Surgery* 2004;8:229–238.
- Slutsky DJ. Management of Dorsoradiocarpal ligament repairs. *Journal of the American Society for Surgery of the Hand* 2005;5:167–74.
- Slutsky DJ. The use of a volar ulnar portal in wrist arthroscopy. *Arthroscopy* 2004;20:158–163.
- Slutsky DJ. Volar Portals in Wrist Arthroscopy. *Journal of the American Society for Surgery of the Hand* 2002;2:225–232.
- Slutsky DJ. Wrist Arthroscopy Portals. In Slutsky DJ, Nagel DJ, ed. *Techniques in Hand and Wrist Arthroscopy*. Philadelphia: Elsevier, Inc., 2007 (in Press).
- Slutsky DJ. Wrist arthroscopy through a volar radial portal. *Arthroscopy* 2002;18:624–630.
- Steinberg BD, Plancher KD, Idler RS. Percutaneous Kirschner wire fixation through the snuff box: an anatomic study. *J Hand Surg [Am]* 1995;20:57–62.
- Taras JS, Sweet S, Shum W, Weiss LE, Bartolozzi A. Percutaneous and arthroscopic screw fixation of scaphoid fractures in the athlete. *Hand Clin* 1999;15:467–473.
- Tham S, Coleman S, Gilpin D. An anterior portal for wrist arthroscopy. Anatomical study and case reports. *J Hand Surg [Br]* 1999;24:445–447.
- Thurston AJ, Stanley JK. Hamato-lunate impingement: an uncommon cause of ulnar-sided wrist pain. *Arthroscopy* 2000;16:540–544.
- Tomaino MM, Elfar J. Ulnar impaction syndrome. *Hand Clin* 2005;21:567–575.
- Trumble T, Nyland W. Scaphoid nonunions. Pitfalls and pearls. *Hand Clin* 2001;17:611–624. 82.
- Trumble TE, Gilbert M, Vedder N. Isolated tears of the triangular fibrocartilage: management by early arthroscopic repair. *J Hand Surg [Am]* 1997;22:57–65.
- Trumble TE, Gilbert M, Vedder N. Arthroscopic repair of the triangular fibrocartilage complex. *Arthroscopy* 1996;12:588–597.
- Verhellen R, Bain GI. Arthroscopic capsular release for contracture of the wrist: a new technique. *Arthroscopy* 2000;16:106–110.
- Viegas SF. Midcarpal arthroscopy: anatomy and portals. *Hand Clin* 1994;10:577–587.
- Viegas SF, Patterson RM, Hokanson JA, Davis J. Wrist anatomy: incidence, distribution, and correlation of anatomic variations, tears, and arthrosis. *J Hand Surg [Am]* 1993;18:463–475.
- Viegas SF, Patterson RM, Peterson PD, et al. Ulnar-sided perilunate instability: an anatomic and biomechanical study. *J Hand Surg [Am]* 1990;15:268–278.
- Viegas SF, Yamaguchi S, Boyd NL, Patterson RM. The dorsal ligaments of the wrist: anatomy, mechanical properties, and function. *J Hand Surg [Am]* 1999;24:456–???
- Werner FW, Glisson RR, Murphy DJ, Palmer AK. Force transmission through the distal radioulnar carpal joint: effect of ulnar lengthening and shortening. *Handchir Mikrochir Plast Chir* 1986;18:304–308.
- Whipple TL. Arthroscopy of the distal radioulnar joint. Indications, portals, and anatomy. *Hand Clin* 1994;10:589–592.
- Whipple TL. The role of arthroscopy in the treatment of scapholunate instability. *Hand Clin* 1995;011:37–40.

Hand Surgery Update

